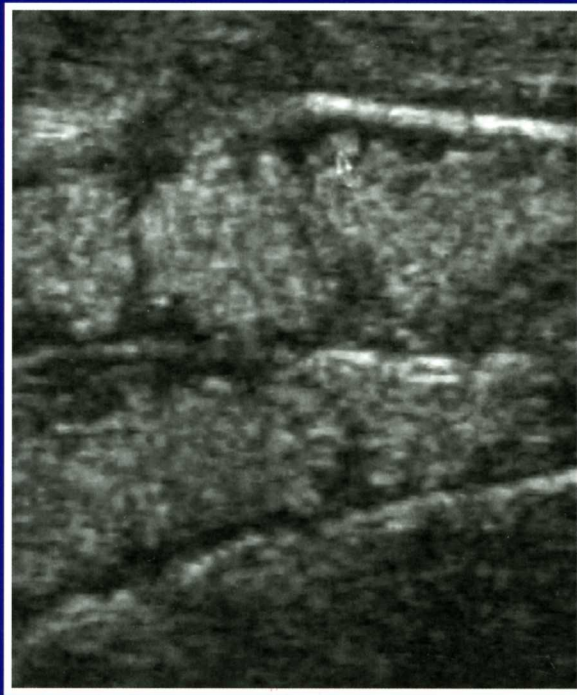


Mikhail CHEBANOV and Elena GALICH

**ULTRASOUND DIAGNOSTICS
FOR STURGEON BROODSTOCK
MANAGEMENT**



Mikhail S. Chebanov Elena V. Galich

**Ultrasound Diagnostics for Sturgeon
Broodstock Management**

Krasnodar 2009

Authors:

Professor, Dr. Sc. (Biol) Mikhail S. Chebanov
Dr. Elena V. Galich
Federal Centre of Selection and Genetics for Aquaculture, Krasnodar, Russia

Translation from Russian:

Dmitry V. Ananyev
Prof. Mikhail S. Chebanov

Reviewers

Professor, Dr. Sc. (Biol.) George A. Moskul
Department of Water Biol. Resources and Aquaculture
Kuban State University, Russia

Professor, Dr. Sc. (Biol.) Andrey K. Bogeruk
Pedigree Fish Breeding Centre, Moscow
Ministry of Agriculture, Russian Federation

ISBN 978-5-93491-259-9

South Branch Federal Center of Selection and Genetics for Aquaculture
59 Gimnasitsheskaya St., 350000, Krasnodar, Russian Federation
Tel./Fax: +7 (861) 262-96-71, +7 (861) 262-25-59
E-mail: Chebanov@sturg.kuban.ru, MChabanov@gmail.com
Web: www.sturgeon.su

Introduction

Overfishing and habitat degradation leads to dramatic decrease in sturgeon stock abundance, especially in Eurasia (Williot, 1989, Barannikova et al., 1995). So far, measures aimed at conservation of sturgeon have been ineffective and not sufficient for sustainable sturgeon fisheries (Williot et al., 2002).

Establishment of the World Sturgeon Conservation Society (WSCS) in 2003 allows to activate and coordinate international efforts for development of research programmes on conservation of sturgeons. Regularly held International Symposia on Sturgeons have allowed to summarize the results of these activities (Rosenthal et al., 1999, 2002, 2006). The strategy of global sturgeon conservation has been developed in the frame of Ramsar Declaration (2006).

For instance, sharp decline in number of released hatchery produced sturgeon juveniles in Sea of Azov and Caspian Sea has been associated with the lack of wild breeders collected for reproduction, which requires accelerated establishment of domestic broodstock of different sturgeon species. This requires to develop guidelines for broodstock management based on the Best Environmental Practices and Best Available Technology, that is complicated by the lack of external sex dimorphism in sturgeons.

One of the limiting factors of development of broodstock management in conservation and commercial sturgeon culture had been the lack of appropriate methods for early sex identification, allowing to increase efficiency of building and utilization of both pedigree broodstocks and living gene banks as well as commercial caviar-oriented sturgeon farming.

Our development of a new express ultrasound technique of early sexing and gonad staging enables this problem to be resolved.

Ultrasound diagnostic express technique enables early sexing of juveniles for separation at first males from females (at age 1-2 years), and later to staging females for optimization of broodstock management for artificial reproduction and caviar production. Actually, during one day of non-invasive ultrasound examination, a skilled operator is able to identify sex and maturity stage for 1500 sturgeon specimens.

Authors, intentionally, described different questions related to broodstock management with different depths. The present book has focused on the less known, not reported previously aspects of ultrasound technique of early sexing and other original results of authors' longstanding investigations at

establishment of the largest living gene bank of 8 sturgeon species (Chebanov et al., 2002, 2004, 2006).

In addition, this book is based on the materials collected during domestic broodstock sexing and staging and related trainings conducted by authors in many commercial sturgeon fish farms not only in Russia but also in many other countries.

This technique is not limited by sex and maturity stages determination, but also can be successfully applied for noninvasive broodstock monitoring by evaluation of inner organs state, including detection of anomalies in development, diseases diagnostics, calculation of gonadosomatic index, fecundity, maturity duration prognosis, timing of full ovulation etc. The ultrasound monitoring of broodstocks enables timely correction of basic broodstock holding parameters, including feeding regimes and rates.

The modern ultrasound scanning systems supplied by software for image optimization and scanning regimes have been used in Medicine. The novel ultrasound technology enables investigation of tissue structure (Tissue Harmonic Image, 3D, 4D echography, matrix and panoramic scanning), that allows to enhance quality of visualization and perform non-invasive disease diagnostics in accurate and express manner. But, the objective of this book is to assist in wide implementation of cheap and available ultrasound systems in sturgeon culture, especially for broodstock management.

Undoubtedly, this book could not replace the own experience in ultrasound examination, but at the same time, it can become a basis for fast mastering of ultrasound diagnostics of sturgeons. The procedure and accuracy of ultrasound technique is primarily depends on the operator's experience. And, due to the fact that ultrasound technique has been applied in sturgeon culture just recently and insufficient skills of some operators in any case of lead to opinion that this method is complicate and not that accurate. The authors believe that this book will assist in filling the existing lacunas and allows to increase the quality of diagnostics of developmental status of reproduction system of sturgeons.

Authors have been eager to prepare this book before the 6th International Symposium on Sturgeon (China, October, 2009), aiming also at using this book in the frame of the special workshop "Theory and practice in sexing and staging maturity in sturgeons (modern methods)", considering the existing interest in this methods and hope that it will stimulate wide implementation of this method in the sturgeon broodstock management. Despite our desire to do our best, not all the target objectives has been fulfilled and some editorial

mistakes and can be find in the text. So, the authors would be very grateful to all who will provide comments concerning this work improvement.

Acknowledgements

Authors very much appreciate many years understanding of the urgency of this sphere of investigation and organization of special workshops during the International Symposiums of Sturgeons that have been provided by our WSCS collaborators: Harald Rosenthal, Serge Doroshov, Ronald Bruch, Patrick Williot, Martin Bilio, Paolo Bronzi, Mohammad Pourkazemi, Jorn Gessner, Fred Binkowski, Wei Quiwei, Jianbo Chang.

We are much grateful to all specialists of the South Branch Federal Centre of Selection and Genetics for Aquaculture, especially, Chmyr Yu.N., Akhteryanova L.R., Timonina V.A., Merkulov Y.G. for long-term mutual collaboration.

We would like to address special thanks to Ananyev D.V., Krupsky V.N., Stefanov E.V. for valuable assistance in manuscript preparation for publication.

Chapter 1

Basis of Ultrasound Diagnostics in Sturgeon Broodstock Management

1.1 Equipment for sexing in sturgeons using ultrasound

It is well known that ultrasound scanning systems has been widely used for research medicine applications (Palmer et al., 1995). The non-invasiveness of this express technique as well as possibility to view the dynamic images ("cine mode") combined with reliability have made the ultrasound scanning systems a promising Veterinary and Fish farming and research tool (Mattison, 1991; Karlsen et al., 1994; Goddard, 1995).

Biological safety of ultrasound diagnostics

Despite the fact that ultrasound of high frequency can affect animal cells viability and damage DNA "*in vitro*", it has been established that ultrasound of diagnostic intensities is biologically safe and does not cause any clinical impacts (because of short term exposure to the pulse waves used in the ultrasonography).

Express efficiency

The properly arranged sturgeon ultrasound diagnostics procedure is short (up to 10 sec), to exclude some rare or complicated cases like hermaphroditism, abnormalities of reproductive system (ingrowing of connective tissues into generative part of the gonad, tumors and cysts), those requires some extra time (1-2 min) and hence less traumatic (besides stress).

Non-invasiveness

In the course of the fish examination, organs and tissues are not destructed, hence the stressors influence is minimal.

1.1.1 Characteristics of ultrasound waves

Ultrasound is of wave nature and possess physical wave characteristic like: frequency, length, velocity etc. While studying peculiarities of ultrasound waves transmission in the body of sturgeons, the main medias can be singled

out: bones ("scutes" – bony plates), cartilages, soft tissues, gas, those have different acoustic resistance (Table 1.1), enhancement and exhibit different reflection of ultrasound beams (echogenicity).

Table 1.1 Velocity of sound wave propagation (V), density (ρ) and resistance ($Z=\rho V$) of different substances (Palmer et al., 1995)

Substance	V, m/c	ρ , g/cm ³	$Z=\rho V$
air	330	0.0012	41.3×10^{-5}
tissues:	1476-1570	0.928-1.055	1.37-1.66
adipose tissue	≈ 1450		
muscular tissue	≈ 1540		
liver	≈ 1540		
water	≈ 1482		
bone (osseous) tissue	3360-4000	1.85	6.2
cartilaginous tissue	2800-3200	1.65	4.9×10^3

1.1.2 Transducers

An ultrasound scanner for sturgeon examination is typically equipped with a Linear Array 5-10 MHz/40-60 mm transducer, providing ultrasound images of high resolution for fish weight range from 0.5 kg (sterlet) to 50 kg (giant sturgeon), with peak efficiency for fish in between the range 2-20 kg, never mind the species. Moreover, a standard linear transducer provides a low depth of scanning due to rather high sound frequency. Therefore, for large specimens (>50 kg), it is recommended to use convex transducer (Fig 1.1), allowing 2.0–3.5 Mhz and >20 cm depth operation. Unfortunately, transducers of the latter type produce a low resolution (Chebanov, Galich, 2008).

To ensure distinct visualization of fish gonads, minimum linear size of gonad on histological sections should be at least 10-20 times large than ultrasound wave length. Otherwise, the margins of the organs would be indistinct or even invisible.

Once a 5-10 Mhz transducer is used, the minimum size of the structure should be not less than 2 mm. A 3-5 Mhz transducer has the focus depth range from 7 to 9 cm, while 5, 7.5 and 10 Mhz transducers that from 5 to 7, 4 to 5 and 3 to 4 cm respectively.

Progressive attenuation of the sound in the course of tissue penetration depends on its type, density and rate of tissue heterogeneity.

The wave reflection is propagated in the direction to the sound source. Thus, in order to get distinct image, the ultrasound beam should be directed to the gonad (or other experimental organ) at 90° angle, thus ensuring maximum reflection and further visualization.

In some complicated cases and in the course of research, when target echograms should be of high resolution (especially while studying smaller fish), expensive linear transducers of higher frequency range (up to 25 Mhz) may be used, for example, "Esaote" with frequency 12.5 Mhz (Bonput, 2006).

The following types of transducers can be used for the ultrasound diagnostics of sturgeon.

Linear transducer

Sections obtained using such transducers are rectangular in shape. The scanning plane of the transducer is flat, tightly bound to surfaces and proved to be the best choice for examination of organs and tissues in sturgeons.

Sector transducer

In this case sections have a fantail shape, close to triangle one. These transducers may be effectively used if only a small area is available for diagnostics. Similar transducers may be used for fish examination, but considerably more expensive and less than linear ones and less serviceable.

Convex transducer

Section has a form, that is intermediate between shape of linear and selective transducer sections. The transducer of the kind is typically in the standard set of the ultrasound systems. It has a semicircular surface, and can not be tightly bound to experimental part of the fish. In addition, convex transducer, as a rule, has low frequency and, hence relative low resolution capacity, but high depth of ultrasound penetration (scanning). Thus, it is wise to use this type in case of large fish (more than 50 kg in weight) only.

Type, size and operational frequency are the prime transducer characteristics of those defining efficiency of the ultrasound system.




Fig. 1.1 Ultrasound transducers: A - convex; B - linear.

1.1.3 Some field ultrasound scanning systems used in aquaculture**Easi-Scan****Fig. 1.2** Ultrasound scanner "Easi-Scan".**Features**

- 12V battery allows up to three hours continuous operation
- Storage capability for sixty images, including a four second sound tag for each image (stored images can easily be transferred to computer)
- The image is sent from the scanner via radio-wave transmission, removing the need for wires between the scanner and the monitor; and with the option of a battery powered monitor.

Pico**Fig. 1.3** Ultrasound scanner "Pico".**Specifications**

Operation/Image Modes: Standard B mode
 Grey Shades: 256 different shades
 Monitor: 10" diagonal, CRT monitor
 Transducer: 128 element broadband (4.5MHz to 8.5MHz) crystal array vet linear transducer
 Power/Battery: 12V battery attached to the unit
 Physical Dimensions (mm): 280(D) x 195(W) x 95(H)
 Weight: 3 kg (with battery)
 Manufacturer: BCF Technology

Features

- Integrated and tiltable 10.4" high quality colour LCD screen
- 256 frame cine loop memory
- 40GB patient archive
- Inbuilt stereo audible speakers
- DICOM Capability (Option)
- USB port; images can be easily transferred to PC or network with USB memory stick
- Store images and then post measure, annotate and save the subsequent modified image to the patient file

Specifications

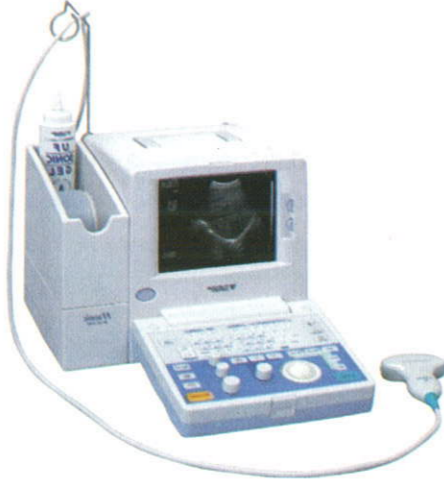Operation/Image Modes: B, B&B, M, Colour, pulsed wave Doppler.
 Grey Shades: 256 grey scales and 8 bit colour. Measurement System: Full measurements package includes different coloured on screen markers for linear, ellipse and trace. Monitor: Integrated & Tilttable 10.4" high quality colour LCD. Transducer: 128 element broadband (4.5MHz to 8.5MHz) crystal array vet linear transducer. Power/Battery: Mains Supply only. Physical Dimensions (mm): 204(D) x 320 (W) x 357(H). Weight: 10 kg.
 Manufacturer: BCF Technology. Web: www.international.bcftechnology.com

Mini-Scan**Fig. 1.4** Ultrasound scanner "Mini-scan". 230 (W) x 190 (H), Weight: 3 kg
 Manufacturer: BCF Technology**Specifications**

Operation/Image Modes: Standard B mode and B/B Mode
 Grey Shades: 256 shades
 Monitor: Integrated high brightness flat panel display with 6.4 VGA LCD
 Transducer: 128 element broadband (4.5MHz to 8.5MHz) crystal array vet linear transducer with 2m cable
 Power Battery: Inbuilt 12V battery
 Physical Dimensions (mm): 150 (D) x 230 (W) x 190 (H), Weight: 3 kg
 Manufacturer: BCF Technology

Features

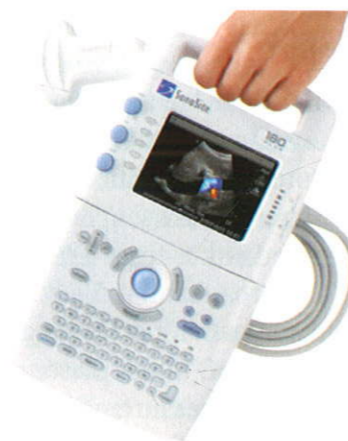- Mini-Scan has storage capability for sixty images; each image is automatically date and number stamped
- Stored images can easily be transferred to computer
- Battery allows up to two hours continuous operation and can be easily charged either from a mains adaptor or the 12V in-car adaptor
- The broadband 4.5 - 8.5 MHz, vet rectal transducer is durable and reliable and comes with a 2m long cable for ease of use and flexibility
- Dustproof, tough plastic casing
- Calliper measurement system provides accurate measurement capability.
- Web: www.fukuda.com.

Fukuda UF - 4100**Fig. 1.5** Ultrasound scanner "Fukuda-4100"**Features**

- Multi-Frequency Function enables selection of 3 frequencies in each Transducer
- High-End image Control Function as Zoom, Image Processing, and Variable Focal Zones
- Built-in Large Track Ball allows ease of use
- B, B/B, M, and B/M Mode display
- General Calculation Package for OB, Distance, Area, Volume, and Cardiovascular
- Wide Band, High sensitivity new optional probes

SonoSite 180 PLUS**Features**

- Composite video output (NTSC/PAL) to videocassette recorder, video printer or external monitor
- Connect to PC via PC Direct cable or via SiteStand® mobile docking station to download high resolution bitmap images
- ECG/serial connector
- Integrated trackball for navigation

**Fig. 1.6** Ultrasound scanner "SonoSite 1800+".**Specifications**

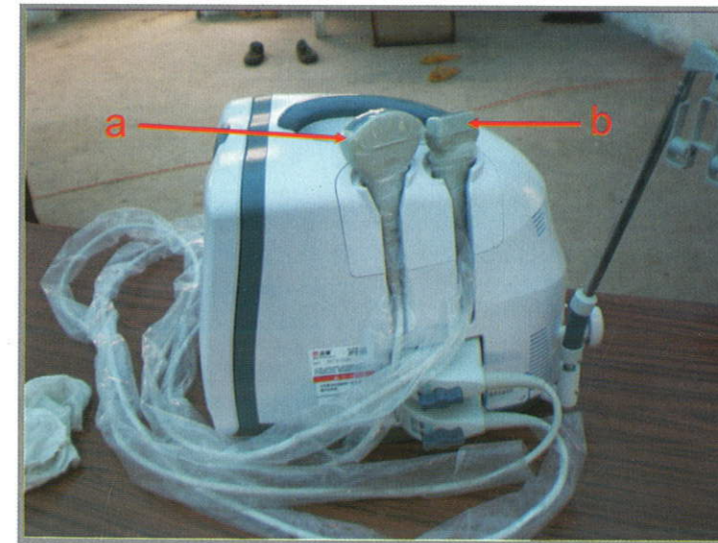
Display Mode: B, B/M, M
 Gray Scale: 256 levels
 Cine Memory: 64 frames
 Monitor: 7-inch, CRT
 Standard Probe: Convex 3/3.5/4 MHz
 Input/Output Connectors: Video IN/OUT, Printer remote, Freez on/off (Foot SW)
 Power requirements: 100-120, 200-240VAC, 50/60Hz
 External Dimensions (cm): 33.2(W) x 31.2(D) x 26.0(H)
 Weight: 10 kg

Specifications

Imaging Modes: 2D, Zoom, Narrow imaging sector, Color power Doppler, Pulsed wave Doppler (option), Directional color power Doppler, Continuous wave Doppler (option), M-mode, Tissue Harmonic Imaging (option). Monitor: Integrated 5" (12.7 cm) TFT color Liquid Crystal Display with brightness and contrast controls. Storage: internal 119 image memory (maximum) for off-line printing and review. Power: Operates via battery or AC power — 1.5 to 4 hours on fully charged. Physical Dimensions (cm): 6.35 (D) x 19.3 (W) x 33.8 (H). Weight: 2.6 kg. Manufacturer: SonoSite Inc. Web: www.sonosite.com.

1.1.4 Mobile data and analytical system on the basis of the ultrasound scanner Mindray DP-6600

The recommended for wider application in sturgeon culture portable ultrasound scanner Mindray DP-6600 (www.mindray.com, China) proved to be a better choice than the "My Sono-201" system described by Chebanov et al. (2004) both in terms of its price and resolution capacity of a 10-inch monitor with option of progressive line scanning (Fig. 1.7).

**Fig 1.7** Ultrasound portable scanning system Mindray DP-6600: a – convex transducer; b – linear transducer.

The main features of Mindray DP-6600 system are as follows:

- transducer connectors for 2 transducers;
- scanning angle from 40 to 128 degree (depending on transducers);

- depth of scanning from 25.9 to 246 mm (depending on transducers);
- 256-frame cine loop;
- 115 images memory;
- built-in image archive for >200 reports storage;
- video output;
- 2 USB ports;
- software for measurements and calculations.

The features of this ultrasound system enable the recording of scanning procedure (the system is to be connected to PC via video output) for successive analysis and training of specialists, as well static frame making. The storage of information is enabled both in flash memory of the scanner and in external USB storage carrier. This feature is very useful and allows to enhance considerably efficiency of the operation with this scanning system. The scanning system in combination with a personal computer proved to be an effective echogram processing complex (Fig 1.8).

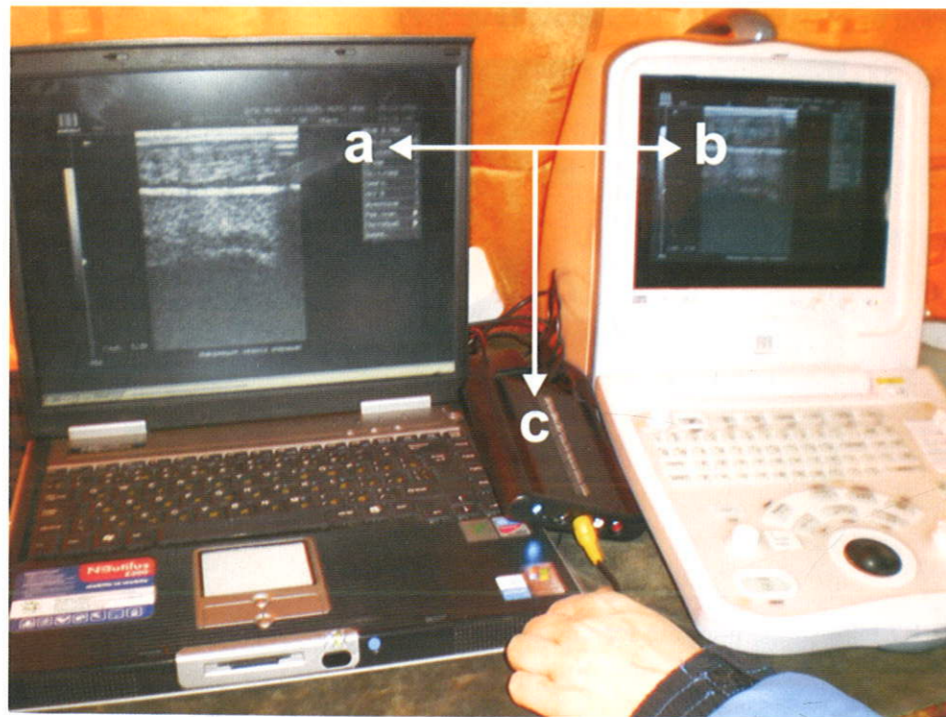


Fig. 1.8 Mobile data and analytical system on the basis of the ultrasound scanner Mindray DP-6600: a – notebook; b – ultrasound scanning system; c – MPEG2-Encoder.

1.2 Work Place Organization

The early live detection of sex and identification of stages of gonadal development require the special organization of work station (operator's place) (Fig. 1.9).

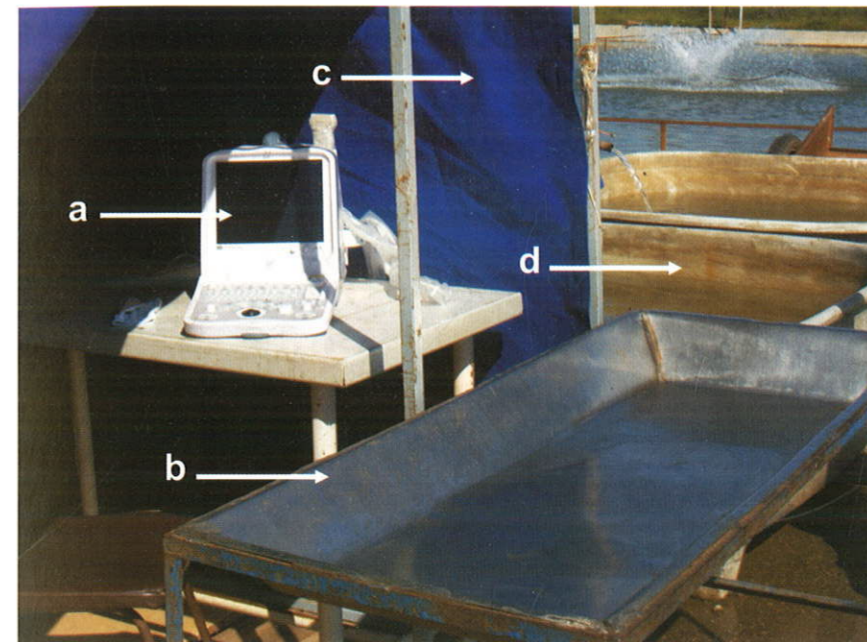


Fig 1.9 Equipment of mobile data and analytical system on the basis of the ultrasound scanner Mindray DP-6600:
a - ultrasound scanner; b – special stainless table for fish; c – tent to protect the scanner monitor from direct sun beams; d – fish collecting tanks.

The work place should meet the following requirements and includes:

- a table for ultrasound equipment, large enough to enable the operator to conduct video examination and written records;
- a customized (metal or wood) table with high sides for fish holding;
- persons who handle fish should have free access to fish table;
- AC/DC power source (socket) close to the table;
- the work place should have moderate illumination not to obstruct the reading of the video information on the monitor;

- the operator performs scanning in sitting position and at the same time watching the video image on the LCD monitor;
- the fish collecting tanks should be located in the close location from the ultrasound complex. Large individuals (>50 kg) operation may require anesthetics (MS-222, clove oil) administration (Podushka, Chebanov, 2007).

All the equipment should be installed, connected and adjusted prior to sampling procedure.

Fish is placed on its right side on the customized table, with either ventral (head to the left) or dorsal (head to the right) side towards the operator. Fish should be held in the same position during all the process of scanning, which can take from few seconds to few minutes (Fig. 1.10).




Fig. 1.10 Example of large fish (immature female beluga) positioning and holding during ultrasound examination of maturity stage.

One person can hold smaller fish while two assistants are needed to hold the head and tail of larger fish (about 3-4 kg). It is discouraged to conduct scanning under unfavourable environmental conditions (heat, freeze, wind). Scanning on a strong wind can cause desiccation and damage the gills and cutaneous covering of sturgeon.

1.3 The resolving capacity of sonography method for the sex Early life-time diagnostics and gonads maturity stages determination for sturgeons

The ability to identify an image and to diagnose sex and stages of maturity will depend (if the recommendations for equipment parameters are followed) on the factors as follows: species membership; age; size; conditions and mode of rearing; nutritional state; time of running investigations (period of wintering, fattening, spring period (withdrawal from wintering) etc.); conditions of maintenance prior to investigations (feeding, long or short time alimentary deprivation).

The diagnostic markers for the sex determination are as follows:

- localization of germinal tissue in the gonad (medial, lateral etc.);
- absence or presence of the gonadal tunic;
- character of the surface and margins of the gonad, unbroken or broken margin, straight or curved margin;
- echogenicity of generative tissue, which is revealed by different brightness on the screen image;
- homogeneity or heterogeneity of gonad tissues structure;
- relative distance from the genital opening and structure of the caudal margin of the gonad.

The relative and absolute sizes of gonad and its germinal tissue character, as well as the degree of the signal damping, associated with changes in gonad structure have the decisive meaning at staging of gonad maturity.

It should be noted that during overripening and resorbing of eggs and testes, the echogenicity of tissues is changing. Hyperechoic testicular tissue becomes anechoic or hypoechoic, while anechogenic ovarian tissue – hypoechoic.

The dynamics of individual fish maturation, age and size of fish at anatomical and cytological sex differentiation are video-specific and depend on temperature regimes of holding and rearing, as well as feeds quality and conditions of intensive feeding. Table 1.2 shows weight and age requirements appropriate for the live sex identification using ultrasound.

The period that follows overwintering (temperature range from 8° to 12°C) is the best time for conducting the early non invasive sex determination at sturgeon hatcheries with natural conditions and for warm water hatcheries after 2 months holding at minimum water temperatures. Before sampling, the fish should be deprived of feed for 12 days (minimum). The less appropriate season for sex identification is a period of intensive feeding when the temperatures are higher than 18°C.

Table 1.2 Minimum weight and age requirements for different sturgeon species, including hybrids, when their sex can be non-invasively identified by ultrasonography

Species or hybrid	Industrial (warm water) fish farms		Hatcheries with natural thermal regime	
	Weight, kg	Age, year	Weight, kg	Age, year
Russian sturgeon	2.0 – 2.5	1+ – 2	2.0 – 2.5	2+ – 3
giant sturgeon	7.0 – 10.0	3 – 4	8.0 – 12.0	4 – 5
stellate sturgeon	2.0 – 2.5	2 – 2+	2.0 – 2.5	2+ – 3
sterlet	0.3 – 0.5	1 – 1+	0.3 – 0.5	1+ – 2
Siberian sturgeon	2.0 – 2.5	2 – 2+	2.0 – 2.5	2+ – 3
hybrid Russian sturgeon x Siberian sturgeon	2.0 – 2.5	1+ – 2	2.0 – 2.5	2 – 2+
bester (giant sturgeon x sterlet)	2.5 – 3.0	2 – 2+	2.5 – 3.0	2+ – 3

Regardless of the higher growth rates, the detection of sex in fish reared at industrial sturgeon farms is a difficult task due to substantial fat accumulation and somatic growth prevailing over the development of germinal tissue.

Glossary of special terms on ultrasound investigations

For standardization of obtained images analysis according to results of investigation special terminology was adopted.

Acoustic beam (ray)	a bunch of ultrasound waves produced by a transducer
Acoustic resistance	resistance of tissues to particles oscillation induced by ultrasound waves; visualization of different scanning objects is possible due to acoustic resistance
Anechogenous structures	the objects completely conducting sound (giving no reflections) are seen on the screen as the foci of black colour (liquids)
Attenuation	the decrease in intensity of ultrasonic waves on their passing through the tissues
Boundary	the line dividing two types of tissues differently conducting ultrasound, defined as a region of reflection on the separation boundary
Echogenicity	the ability of tissue (organ) to reflect an ultrasound ray
Echostructures	the structures of tissue or the organs obtained upon ultrasound representation
Frequency	number of full ultrasonic waves of 1 second is expressed in Mhz
Heterogeneous echostructures	these are characteristic of the organs with the different echogenicity
Homogeneous echostructures	these are characterized by the uniform distribution of echosignal of the same intensity all over the organ
Hyperechogenous structures	the objects of high reflecting capacity reflect the larger part of ultrasound rays (bone, gas, collagen) on the screen are visible in the form of bright-white structures
Hypoechogenous structures	the objects partially passing and reflecting ultrasound (soft tissues) are seen on the screen in the form of the dark-grey spots
Longitudinally lateral (frontal)	section, passing lengthwise of the long axis of body from one lateral part of body to another one, dividing it into dorsal and ventral parts
Reflection	the change in direction of ultrasonic wave on the borderline of media separation, in this case an ultrasonic ray does not come through the second medium
Sagittal (longitudinal) section	vertical section along the longer body axis

Sensitivity	amplification of reflected ultrasound waves by the ultrasound system; reflected signals from deeper tissues require more intensive amplification than those from closer to the surface regions
Scanning plane	section of organs and tissues, through which an ultrasound ray passes
Transducer	a part of the ultrasound system that directly adjoin the tested object; it transforms electric energy into energy of ultrasound waves and also detects reflected waves and translates them into electric energy
Transversally lateral (transversal)	section, passing at right angles to longitudinal one with a lateral part of body, dividing it into cranial and caudal part
Transversally ventral (abdominal)	section, passing at right angles to longitudinal one with a ventral part of body, dividing it into cranial and caudal part
Velocity	peculiarities of ultrasound wave penetration in a certain media, unit of measure m/s, depends of the wave frequency and acoustic media resistance

Anatomic and topographic characteristics

Caudal	tail part of body
Cranial	head part of body
Dorsal	closer to back
Lateral	closer to the lateral surfaces of body
Medial	closer to the midline
Ventral	closer to the lower wall of belly

False images – artefacts

Acoustic shadow	it appears behind the strongly reflecting or strongly absorbing ultrasound by the structures and is visualized in the form of black band behind investigated objects (“sputes”)
Acoustic enhancement	crossing of the weakly absorbing structures (liquids) by the sound involves the decrease in attenuation of signal and amplification of acoustic energy behind this object
“Cometary tail”	the ultrasound generates the natural vibrations of the object, it appears on the screen after the gas bubbles in the form of light bands behind the object (gas in intestine)
Mirror transformation	the appearance of image from the both sides of the strong reflector (myotomes of muscles – swimming bladder)
Reverberation	getting ultrasound ray between two or more reflecting surfaces looks like the periodically appearing bright arcs

Chapter 2 Sexing and Staging in Live Sturgeons Techniques Overview

It is well known, that external sexual dimorphism is not apparent in sturgeon before sexual maturity (Dettlaff et al., 1993, Doroshov et al., 1997). At present, different techniques of immature sturgeon sexing and gonad staging are available, apart from the ultrasound methods. Among them are (Williot, 2002):

- biopsy and closely-related methods;
- endoscopy;
- sex steroid profiles analysis;
- morphometry.

2.1 Biopsy

Gonad biopsy is a sampling technique which involves collecting of a small piece of gonadal tissue by inserting a special probe (length – 125 mm, diameter – 4.5 mm) (Fig. 2.1) through the ventral side or lateral muscles or by aspiration (Fig. 2.2). The fat tissue prevailed in gonads of fish at period of intensive feeding, so it could be a problem to hit the germinal part of the gonad. So, the application of this technique is restricted generally to the diagnostic sampling of the mature females, beginning from maturity stage II-III and III.




Fig. 2.1 Probe for sturgeon gonads sampling by using biopsy (A); probe with sample of an ovary at maturity stage IV (B).

It is recommended to use size of follicles as a determinant while preselecting mature females using biopsy of sturgeon breeders. For example, females with an oocyte diameter more than 2.8 mm (Siberian sturgeon) (Williot and Brun, 1998, Williot, 2002) have a chance to reach maturity in few month, that should be finally specified in the course of the spring assessment. It is possible to consider minimal weight of oocyte in the sample as a criterion of mature females selection (Russian sturgeon – 16 mg) (Trusov, 1972).

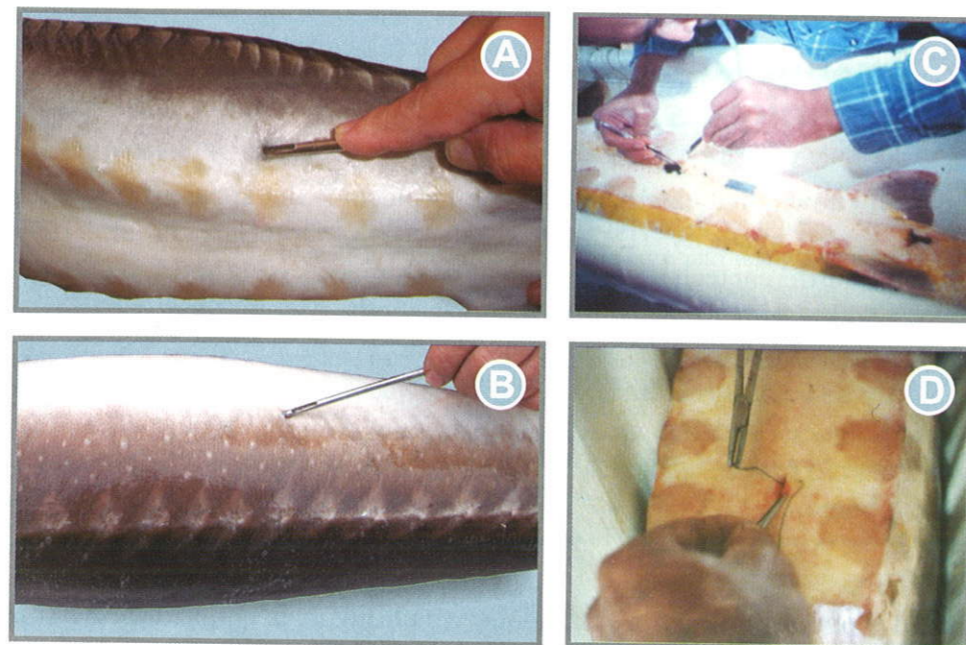


Fig. 2.2 Biopsy sampling using probe (A & B), biopsy sampling by aspiration (C) and suturing (D), (Parauka, 1993).

For immature specimens examination of biopstat is performed under binocular. The type of the sample tissue can be visually assessed (Conte et al., 1988, Parauka, 1993, Van Eenenaam, Doroshov, 1998).

In order to distinguish fat from testicular tissue, biopstat should be placed into 4% formalin. A piece of fat floats, while testicular tissue get sunk (Chapman – referens of Parauka, 1993).

The biopsy technique is time consuming and stressful for the fish. Using anesthetics and taking a biopsy can results in harmful circumstances and infections to the fish. Inevitable the biopsy method can cause losses (up to 5 % of fishes) due to the provoked by biopsy infections.

2.2 Laparoscopy and direct palpation

Small and hardly available for visual examination gonads can be examined by palpation. Sex determination involves a careful inserting a finger through the cut into the body cavity in order to study the shape, size, tissue structure of the gonad by touch (Bruch et al., 2001). The finger should be properly disinfected (Fig. 2.3).

The male and female gonads are easily differentiated by palpation. The ovary is not membrane-bound and tactually appears rough. The testis is covered with a thin tunic and feels smooth while finger examination. The difference between testicular and ovarian tissues structure are well-defined at all maturity stages (Conte et al., 1988, Hochleithner, Gessner, 1999). As Van Eenenaam et al. (2001) reported that one skilled operator can perform sexing fish up to 300-500 during 1 day.

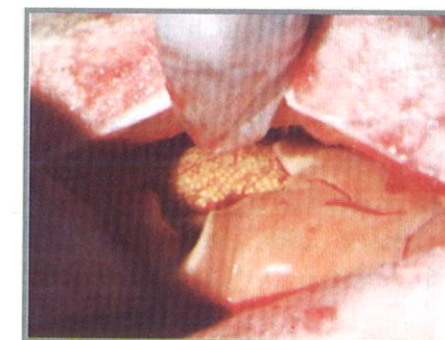


Fig. 2.3 Direct palpation of ovary (Bruch et al., 2001).

At laparoscopy technique, a sample can be taken through a small incision (2 cm) in the ventral body wall of the examined fish. Direct observation of the gonad can be performed using an otoscope (Fig. 2.4) with battery operated light source (Conte et al., 1988, Powell, 2008).

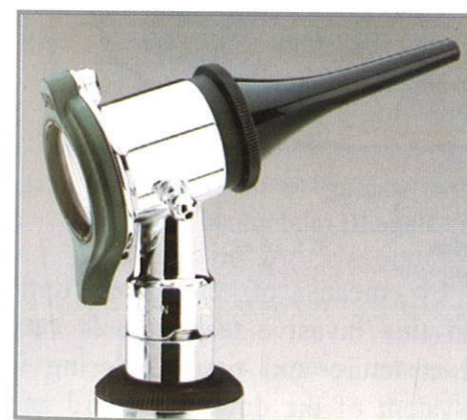

Fig. 2.4 Otoscope for direct observation of sturgeon gonad at laparoscopy.

This technique constraints are equal to those of the biopsy. Direct gonad palpation through the cut into the body cavity is a modification of the surgical method. The precision of this method is higher than that of biopsy, but it proved to be more traumatic, requires suturing and takes more time.

2.3 Endoscopy

Endoscopy – is more advance method of studying gonads in sturgeons. This technique allows the visual studying of gonads with the help of such surgical diagnostic tool for medical examinations of the urino-genital system diseases as cystoureteroscope or borescope (Fig. 2.5).

The duration of one specimen diagnostic examination is ranged from 1 to 5-10 minutes. The probe of borescope is introduced into the body cavity through a punch in the ventral wall of a sampled fish (like at biopsy) or through the urogenital opening for mature fish.



Fig. 2.5 Endoscopic system for sexing and staging (with endoscopic image of *A. gueldenstaedtii* female gonad at maturity stage III (abdominal incision)).

Gonad examination is performed by means of the fiber optic system of the device. The resolution of this invasive technique is very high (Safronov et al., 2006). Detailed structure and tissue coloring is well visualized by means of the optic system of the device (Kynard and Kieffer, 2002, Safronov et al., 2006).

A merit of all mentioned anatomical methods is a rather moderate price of the equipment. Gonad examination is performed by means of the fiber optic system of the device. The resolution of the technique is very high. Detailed structure and tissue coloring is well visualized by means of the optic system of the device.

General contraindication for all anatomical methods is their invasiveness. Penetration into the body cavity can cause the poor physiological state of a

sampled fish, potentially it can be a very strong stressors affecting maturity performance of the breeders. Moreover, anatomical technique requires further monitoring of fish state and suturing.

2.4 Sex steroid profiles analysis

This alternative non-lethal technique for early sexing of fish to estimate the level of such sex steroids as testosterone (T), 11-ketotestosterone (11KT), estradiol (E), that can be measured in the serum of wild (Akhundov, 1997, Barannikova et al. 2005, Cheapa et al., 2002, Webb et al., 2002, Semenkova et al., 2005) and farmed (Amiri et al., 1996, Akhundov, 1997, Semenkova et al., 2006) sturgeons has been widely used.

Akhundov (1997) reported (Table 1) that this technique allows to reveal sex differences (associated with T and E serum concentration) of stellate sturgeon juveniles as early as at age of 12 months.

Table 3.1 Variations in level of blood serum sex steroids in *A. stellatus* juveniles at different stages of gonad development (Akhundov, 1999).

Age, month.	Sex	Weight, g	State of gonad	Estrogen (E), ng/ml	Testosterone (T), ng/ml	E/T
2	♀	3.3 ± 0.42	early differentiation	1.0 ± 0.1	8.5 ± 0.3	1/8
	♂	3.1 ± 0.37	-/-	1.0 ± 0.1	8.3 ± 0.5	1/8
3	♀	11.1 ± 0.75	early differentiation	2.6 ± 0.2	17.3 ± 0.6	1/7
	♂	11.3 ± 0.67	-/-	2.3 ± 0.2	18.8 ± 0.9	1/8
4	♀	30.5 ± 2.26	anatomical differentiation	4.0 ± 0.5	31.6 ± 1.5	1/8
	♂	29.8 ± 2.18	early differentiation	4.3 ± 0.4	32.1 ± 1.6	1/7
5	♀	55.7 ± 3.09	cytological differentiation	5.8 ± 0.4	47.3 ± 2.3	1/8
	♂	54.6 ± 3.78	anatomical differentiation	5.5 ± 0.3	44.8 ± 1.9	1/8
7	♀	69.9 ± 4.59	cytological differentiation	7.6 ± 0.7	59.7 ± 2.9	1/8
	♂	68.3 ± 4.21	anatomical differentiation	6.6 ± 0.5	55.7 ± 2.2	1/8
10	♀	121 ± 8.3	maturity stage I- II	14.7 ± 1.0	93.4 ± 7.6	1/6
	♂	120 ± 7.9	cytological differentiation	7.2 ± 0.5	185.6 ± 11.9	1/26
12	♀	184 ± 12.1	maturity stage I-II	15.8 ± 0.9	102.2 ± 6.9	1/6
	♂	182 ± 14.7	cytological differentiation	7.1 ± 0.6	208.3 ± 12.9	1/29

Webb et al. (2001) reported that content of T in serum in white sturgeon (*A. transmontanus*) males at maturity stage II was higher than that in females (Fig. 2.6). This characteristic can be used for early differentiation between sex and different stages of maturity.

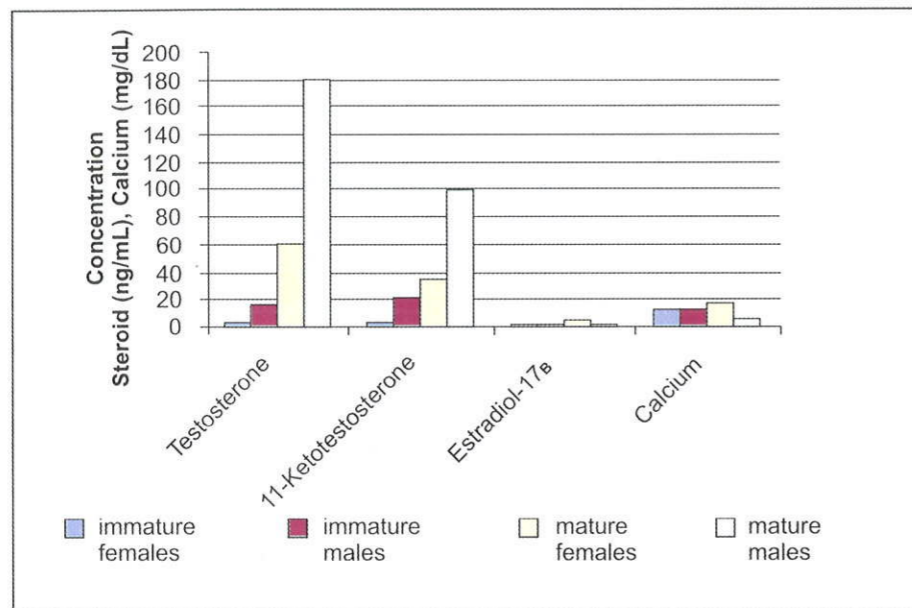


Fig. 2.6 Plasma sex steroids and calcium (as index of vitellogenin) concentrations in mature and immature wild (Webb et al., 2002) white sturgeons (*A. transmontanus*).

Semenkova et al. (2006) confirmed this conclusion, but indicated that its effective (reliable) application of this technique requires monitoring of reproductive system state and measurements of T, 11KT and E2 in females and males of various ages being performed in certain sturgeon farms.

Note that this method requires that during the blood sampling all the fish should be tagged. When the analysis results are obtained, the fish should be recaptured in order to separate sexes. This procedure proved to be labour intensive often resulting in mistakes during the tagging.

Hence, the current disadvantage of this method is extra labor to handle the fish twice (at first for sampling and tagging and secondly for separating females from males), and labor to just spin down the blood samples (up to 5,000-10,000 at rather large sturgeon farms).

2.5. Morphometry

The method of the urogenital region morphometry has been described (Fig.2.7) by Fuji et al. (1987, reference of Billiard, 2002). Some sex differences of morphometric character (E) in urogenital regions in sturgeon hybrid (bestor) from 3 years of age have been found.

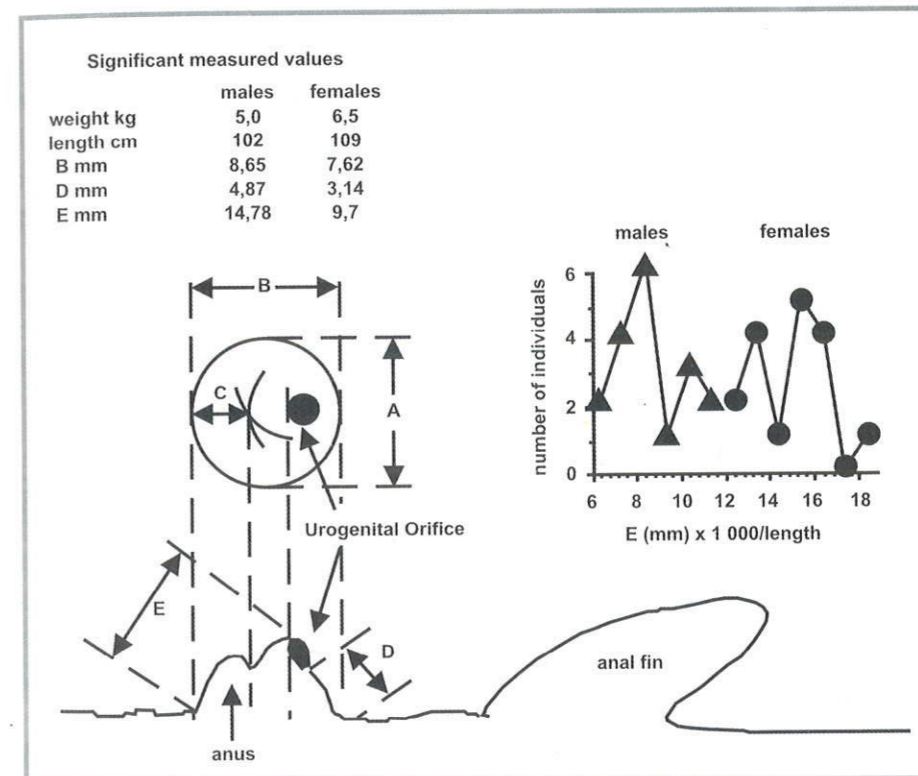


Fig. 2.7 The method of the urogenital region morphometry (Fuji et al., 1987 - from Billard, 2002).

Few most informative indices of craniological measurements in live sturgeons have been statistically identified (Fig. 2.8), enabling the possibility of sexing by using biometrical method has been shown by the example of the *A. ruthenus* and *A. gueldenstaedtii* reared in our Centre (Maltsev and Merkulov, 2006).

The discriminant equations obtained on the basis of this approach can enable easy sex determination of adult Russian sturgeon.

$$D^2 = - 36.7303 - 0.696098 I + 0.193362 Q + 101.344 I/Q + 12.5249 E/H$$

But morphometric methods have not been developed to full extent and their use is restricted to some experimental applications. Hence, they could not be recommended for wide use in broodstock management practice, despite their simplicity.

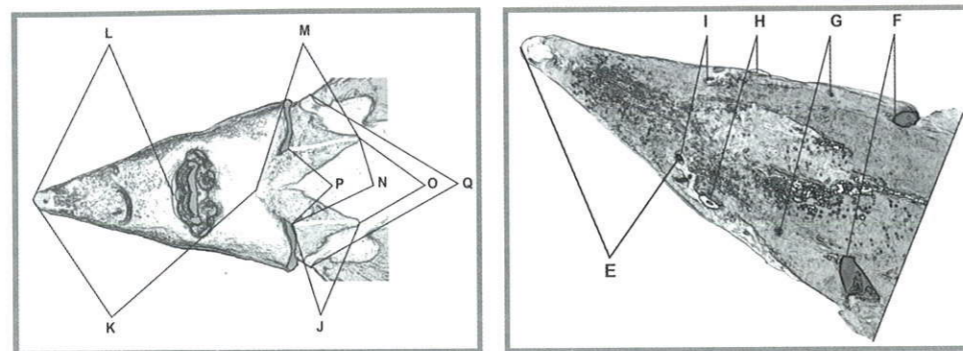


Fig. 2.8 Craniological measurements (Maltsev and Merkulov, 2006).

2.6 Revealing of some external sex traits in adult sturgeons

Vladikov (1931) revealed, for the first time, that paired fins of sterlet females are some longer than that of sterlet males.

Billard (2002) reported that the ventral part of the body in males of Adriatic (*A. naccarii*), Siberian (*A. baerii*) and Russian (*A. gueldenstaedtii*), beluga (*H. huso*) sturgeons is darker than in females. Scutes in females of mature white sturgeon (*A. transmontanus*) became soft due to mineralization during vitellogenesis.

Examination of adult specimens of the North American sturgeons as follows: white (*A. transmontanus*), Atlantic (*A. oxyrinchus*) and shortnose (*A. brevirostrum*) allowed to identify few external morphological sex differences (Vescei et al., 2003) for example males have urogenital opening in a shape of a letter **Y**, while that of females looks like a letter **O**. Accuracy was high in live fish (82%).

Sexual dimorphism expressed by the shape and structure of twin fins, typical for many bony fishes has been revealed by S. Podushka (2008) in farmed Amur sturgeon breeders (*A. schrenkii*). As it is presented on the figure, the shorter and rounded pectoral fins are observed in mature females (Fig. 2.9 "A"), while fins of males are of larger size and have a sharp shape (Fig. 2.9 "B"). These differences, as Podushka reported, can be visible in farmed specimens of Amur sturgeon even from the back side of fish in the tank.

Similar differences have been recorded also in the structure of the pelvic fins of this species breeders. However, it is not evident if this sign depends on the sexual maturity of Amur sturgeon or can be encountered also in immature specimens of this species. Similar differences have not been revealed for Amur sturgeon in the wild (Podushka, 2008).

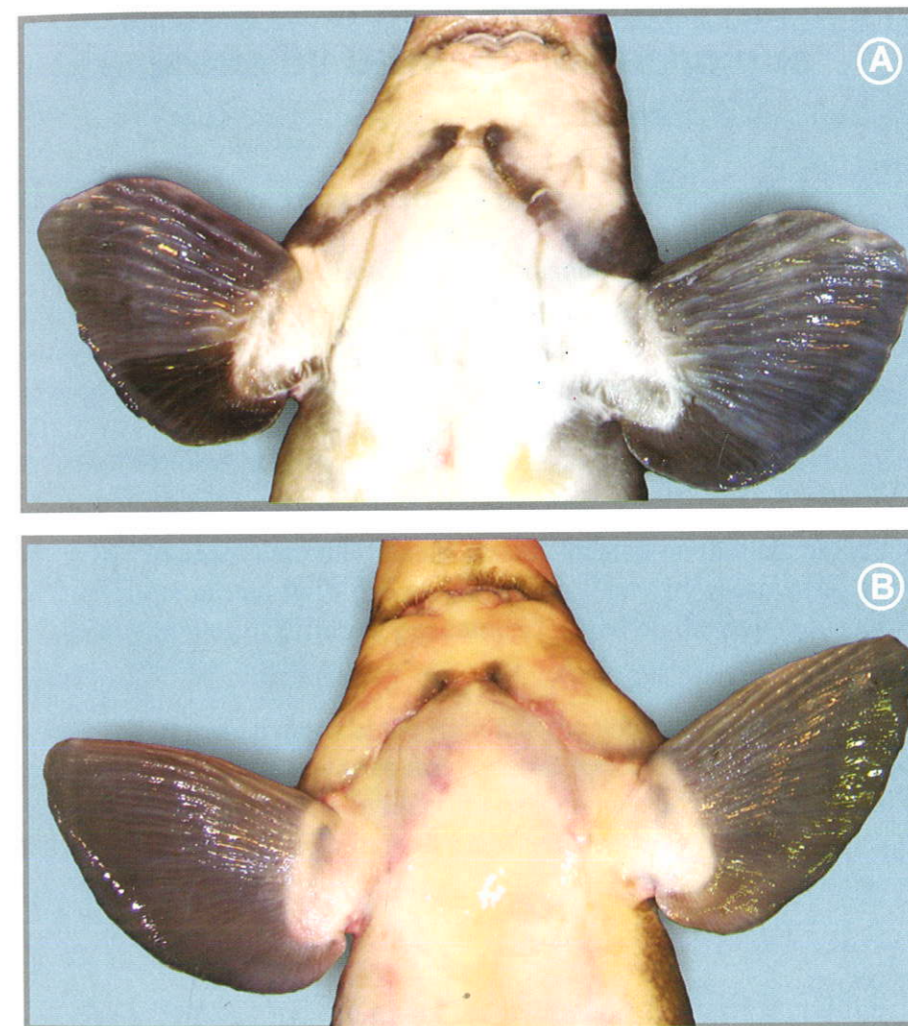


Fig. 2.9 Shape of pectoral fins in farmed Amur sturgeon specimens: A – female, B – male (Podushka, 2008).

Chapter 3

Anatomic Structure and Non-invasive Detecting of Inner Organs and Tissues in Sturgeons by Ultrasound Technique

3.1 Anatomic structure of inner organs

The successful implementation of the ultrasound diagnostics implies clear understanding of sturgeon anatomy peculiarities. The detailed description of the sturgeon anatomy is beyond the scope of this work, so, this subject will be considered in brief, as regards the objectives of the present work.

3.1.1 Reproductive system

Ovaries

The ovaries (*ovarium*) are the female gonads located on the lateral side of the body cavity, connected with dorsal wall of the body by mesovaria. They are composed by ovules of different generation located on the ovigerous lamellae.

Testes

The testes (*testis*) are located at the right and the left from the digestive system and as distinct from the ovaries are covered by connective tissue tunic and have lobulose structure. The oviduct funnels connected with the genital ducts are located at the lateral side in males and females.

3.1.2 Excretory system

Kidneys

The kidneys (*ren*) are located along the intermediate intestine and the colon. They are transpierced by blood vessels and covered by a membrane.

Ureters

The renal ducts function as the ureters (*ureter*) and spermaduct (*vas deferens*). The ureters begin at the front part of the kidney at its external side by single renal tubules forming the common duct with the oviduct funnel.

3.1.3 Digestive system

The digestive system of sturgeons appears to be an intermediate between that of cartilaginous and bony fishes (Fig. 3.1). The peculiarities of the digestive system, increasing the internal absorption surface area of the digestive epithelium, are: the set of loop formed by the intestines (like in bony fishes) and spiral valve preservation in the midgut area, which is typical for cartilaginous fishes (Gurtovoy et al., 1976).

Pharynx

The short pharynx is connected with the oesophagus, that passes to the cardiac part of the stomach. Oesophagus muscles consists of (comprises) two layers: inner longitudinal and outer circular.

Liver

The liver (*hepar*) is a gland of irregular shape divided into two separate lobes: left and right. The oval gall bladder (*vesica fellea*) is located in the posterior part of the liver and bounds with the duodenum via the bile duct (*ductus choledochus*).

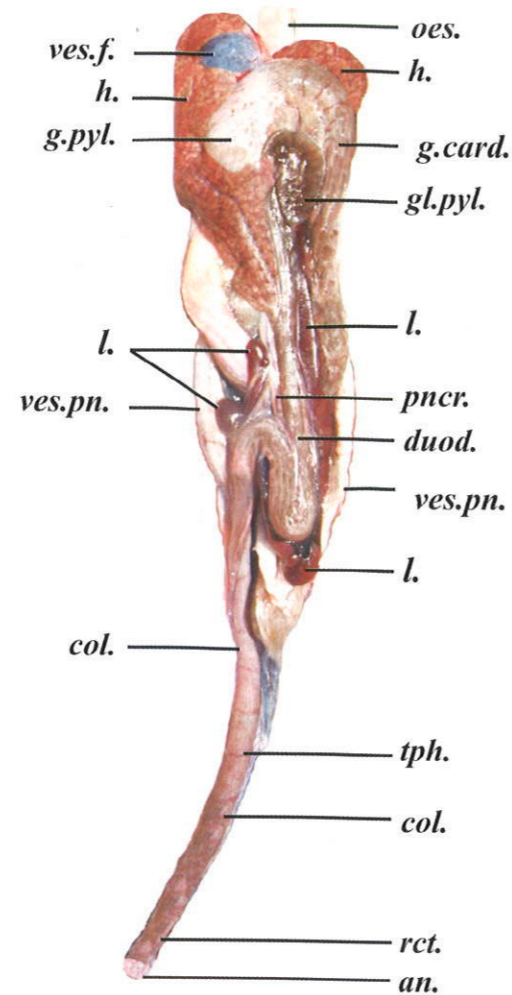


Fig. 3.1 Structure of inner organs of Russian sturgeon

oes. – oesophagus,
h. – liver,
ves.f. – gall bladder,
g.card – cardiac part of stomach,
g.pyl. – pyloric part of stomach,
gl.pyl. – pyloric gland,
l. – spleen,

ves.pn. – swimming bladder,
duod. – duodenum,
pncr. – pancreatic gland,
col. – colon,
tph. – spiral valve,
rct. – rectum,
an. – anal opening.

Stomach

The stomach (*gaster*) is molded (covered) by the liver so only its rear part is visible. It has a siphon-like form and consists of the cardiac and pyloric sections. The inner surface of the stomach forms longitudinal folds. The swimming bladder duct “flows” in the cavity of the cardiac part (*g. card*) of the stomach, from the spinal side.

Pyloric region of the stomach

The pyloric region of the stomach (*g. pylorus*) is connected with the intestine via the pyloric valve, that regulates the intercommunication with the front section of the midgut, so called duodenum, that has a specific porous mucous membrane and separated from the spiral gut by a circular fold – valve.

Pyloric adnexa is embedded in connective tissue, surrounded by serous membrane and form one compact formation of bean-like shape, the pyloric gland (*glandula pylorica*), linked with the mid part of the intestine.

Analysis of the alimentary system structure in all sturgeon species conducted by E. Artyukhin (2008) showed that the stomach of major benthos-feeders *Asipenser* species has a bulbous dilatation (chamber) (Fig. 3.2) intended for crushing of mollusk shells.

The sea species: *Acipenser* (*A. sturio*, *A. oxyrinchus*, *A. medirostris*, *A. transmontanus*, *A. sinensis*) had losted this feature in the course of the transition to predation and have the intestine structure similar to predators of *Huso* genus – beluga (Fig 3.2) and kaluga sturgeons (Artyukhin, 1995).

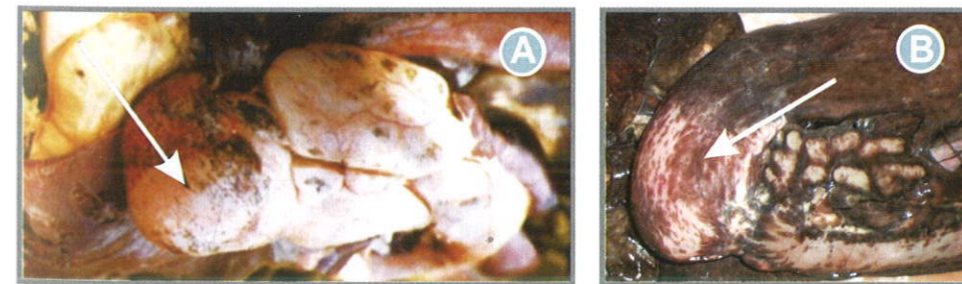

Fig. 3.2 Dissected views of stomach in Persian sturgeon and beluga:
A – view of stomach in Persian sturgeon (Artyukhin, 2008);
B – view of stomach of domesticated form of beluga – “bulbous” dilatation (arrows) is not expressed (domestic broodstock of the South Branch Federal Center of Selection and Genetics for Aquaculture, Krasnodar, Russia).

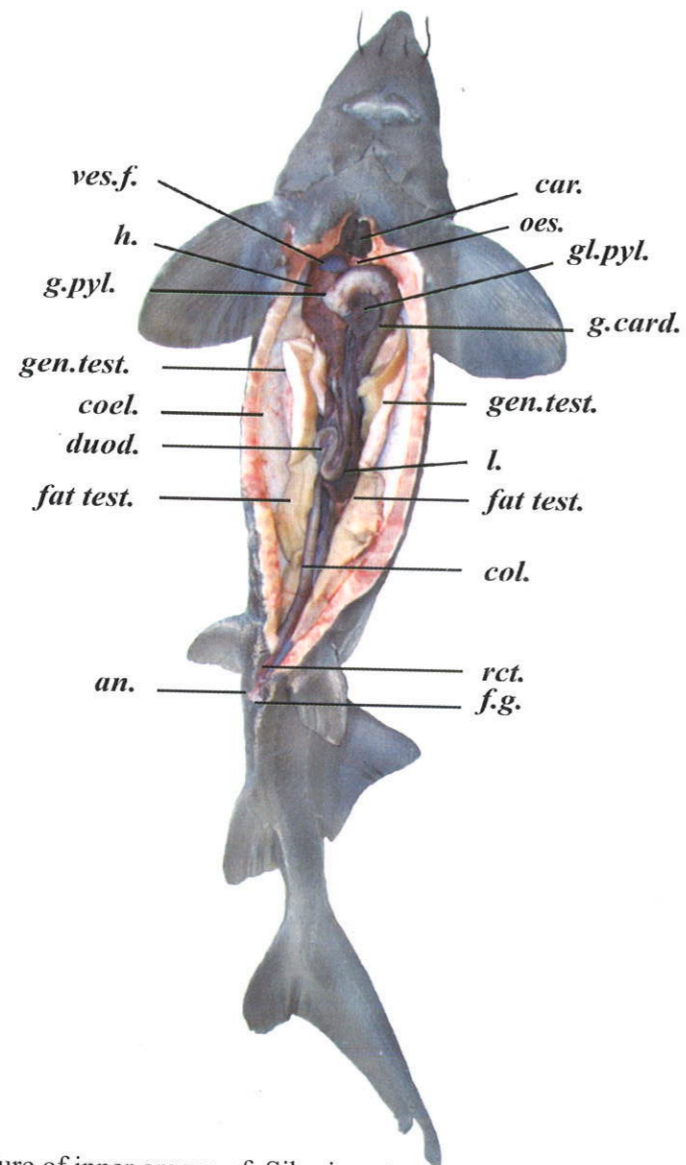


Fig. 3.3 Structure of inner organs of Siberian sturgeon.

car. – heart
oes. – oesophagus,
h. – liver,
ves.f. – gall bladder,
g.card – cardial part of stomach,
g.pyl. – pyloric part of stomach,
gl.pyl. – pyloric gland,
l. – spleen,
ves.pn. – swimming bladder,
duod. – duodenum,
pncr. – pancreatic gland,
col. – colon,
tph. – spiral valve,
rct. – rectum,
an. – anal opening,
f.g. – genital opening.

Pancreatic gland

The pancreatic gland (*pancreas*) is located along the right side of the duodendum, partially turning to the right side. Its front end is close contact with the lappets of the liver and additional lobe of the lien. The single lappets of the pancreatic glands can be visualized in large sturgeon individuals: one located along the outer wall of the duodendum, another linked with the central part of the the liver along the inner edge of the gland.

Duodendum

The duodendum (*duodenum*) – begins near the pyloric gland, goes down to the middle of body, turning up and making loop to the lower border of the liver right lobe or to pyloric gland, turns again left downwards, turning into spiral intestine.

Colon

The colon (*colon*) – is a part of the intestine having thick muscular walls. It is formed by entodermal canal convolution with curled fold of mucous membrane inside. The number of spiral fold turns is ranged from 5 to 10 in different sturgeon species. The smaller folds, linked with smooth walls of the hindgut are located on the inner walls of the intestines, besides the large folds.

Hindgut

The hindgut (*rectum*) is characterized by considerably developed circular muscular layer ending with the anal opening.

Anal opening

The anal opening (*anus*) is the most anterior among four openings (anal, two small abdominal pores, located on the sides, and posterior one – genital) located behind the ventral fins.

3.1.4 Other inner organs

Swimming bladder

The swimming bladder (*vesica pneumatica*) occupies all the dorsal area of abdominal cavity, represents by itself a hollow sac, that inosculates densely with peritoneum by an upper wall. The swimming bladder in all sturgeons is communicated by channel with digestive tube.

Lien

The lien is a glandular organ of V-like shape surrounding the duodendum loop from the left and from the right and underlaying it. The lien consists of the main and supplementary lobes. The additional one is directly adjacent to the liver and the pancreatic gland.

3.2 Non-invasive detection of organs and tissues by ultrasound technique

3.2.1 Scanning procedure schedule

Non-invasive ultrasound express examination is conducted in the frontal and transverse plane. The transducer is pressed down to the body in the region of 3rd-4th ventral scutes (counting from the pelvic fins), so that one edge of the transducer is located above the scutes (Fig. 3.4 & 3.5).



Fig. 3.4 Correct positioning of the transducer in the process of frontal scanning. The transducer is moving from the tail towards the head and backwards.

The optimal section angle is found by bending the transducer (Fig. 3.4 “B”). Then, the transducer is slowly moved in the chosen plane towards the head. At this, the examination is conducted along the entire length of the gonad.

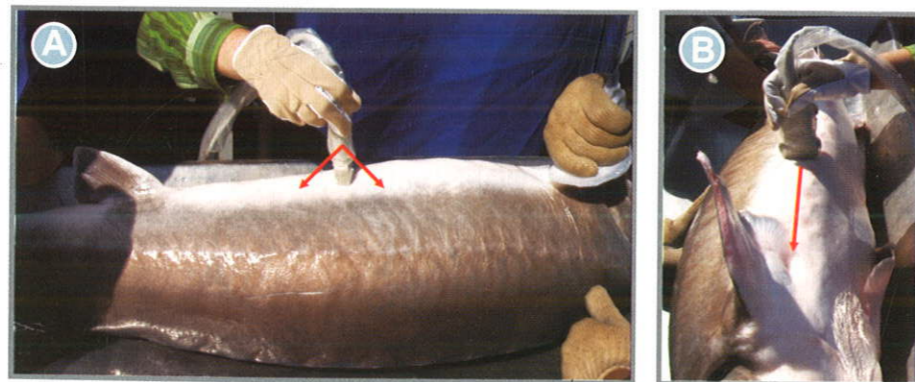


Fig. 3.5 Correct positioning of the transducer at scanning in transversal plane. The transducer moves in direction from tail to the head and backwards.

3.2.2 Peculiarities of organs visualization at frontal ultrasound scanning

The following tissues and organs are visible on the frontal scanning plane (from the scanning plane of the transducer) (Fig. 3.6).

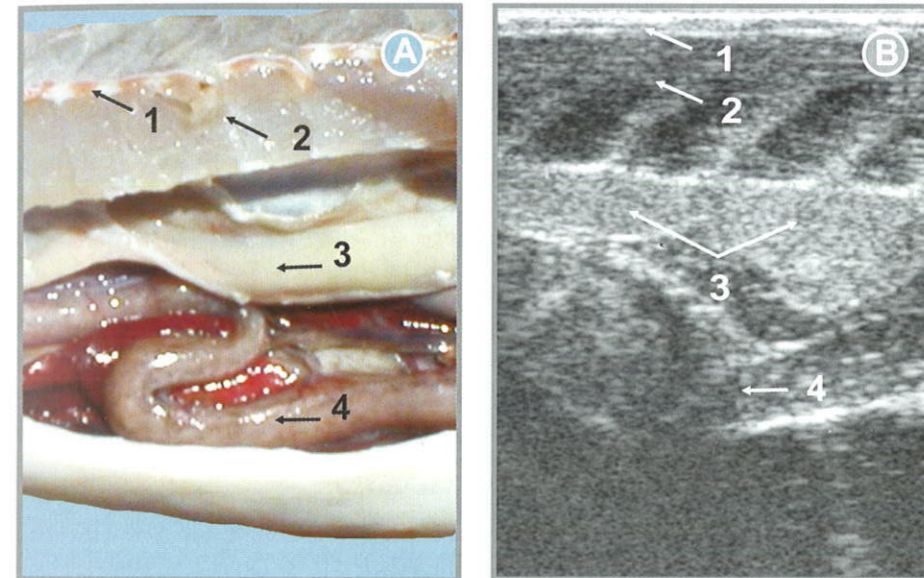


Fig. 3.6 Views of localization of organs and tissues in the body cavity of Russian sturgeon male: A – dissected view; B – frontal ultrasound image (1 – skin and subcutaneous tissue; 2 – muscle fiber; 3 – gonad; 4 – colon).

The following tissues and organs are visible on the frontal scanning plane (from the scanning plane of the transducer):

- skin as a thin hyperechoic region;
- subcutaneous fat tissue, narrow (2-3 mm) stripe with moderate echogenicity;
- muscle tissue – the broad region of mixed echogenicity. The muscle fiber is a region of average brightness (covered horizontally by mixed echogenicity) alternating with muscle walls separated by a connective tissue (on the screen appears as narrow inclined, almost vertical strips, more bright than muscles);
- serous membrane of the abdominal cavity appears as a bright smooth and distinct boundary line;
- gonad itself – different screen images for males and females are associated with echostructure of gonad:

- gonad in males is echohomogeneous structure surrounded by a bright hyperechoic membrane being visualized along the gonad;
- gonad in females is echoheterogeneous without clear boundaries, at dynamic examination appears as overlapping "cloudy" structure;
- can be covered by a tunic and have a structure of complex echogenicity: hyperechoic, hypoechoic, anaechoic or of mixed echogenicity (for more details refer to Chapter 4);
- intestine – it is in the form of longitudinal pipe-like structure with the clear enclosures and consists of two layers: external – hypoechoic and internal – hyperechoic. Gas in intestine is visualized in the form of hyperechoic structures of irregular shape and casts acoustic shadow on the lower located organs (for more details refer to 5.4.5).

In the fishes of small size (less than 4 kg) a second gonad and even muscles and skin (from the other side) are visual under gonad in reverse order (Fig. 3.7).

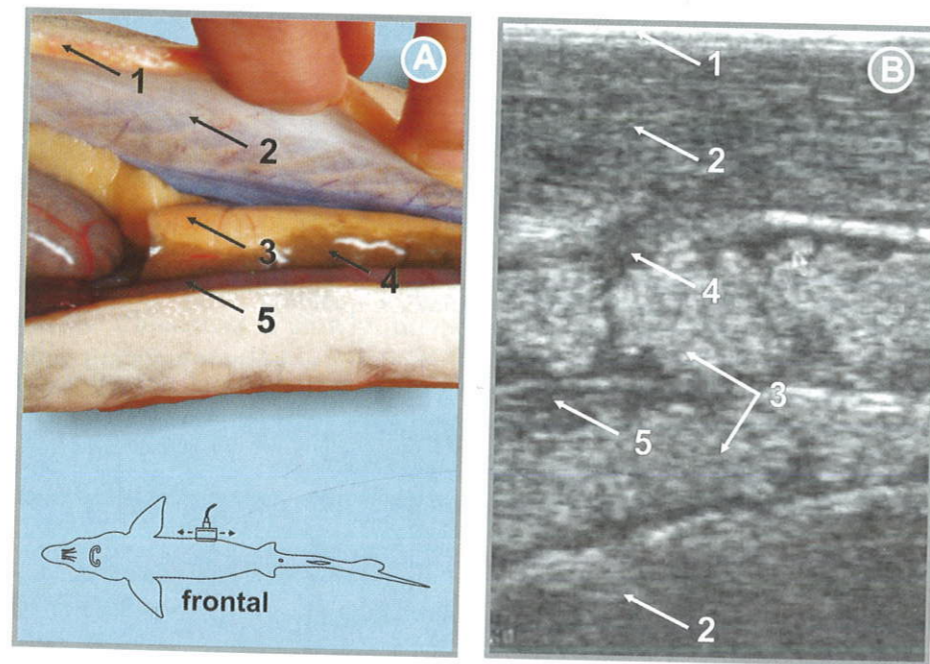


Fig. 3.7 View of organs localization in the body cavity of Russian sturgeon female: A – dissected view; B – frontal ultrasound image (1 – skin and subcutaneous tissue; 2 – muscle fiber; 3 – gonad; 4 – fat; 5 – colon).

3.2.3 Peculiarities of organs visualization at transverse ultrasound scanning

The localization of organs on the screen of monitor is different at transverse scanning, to be compared with the frontal one (Fig. 3.8).

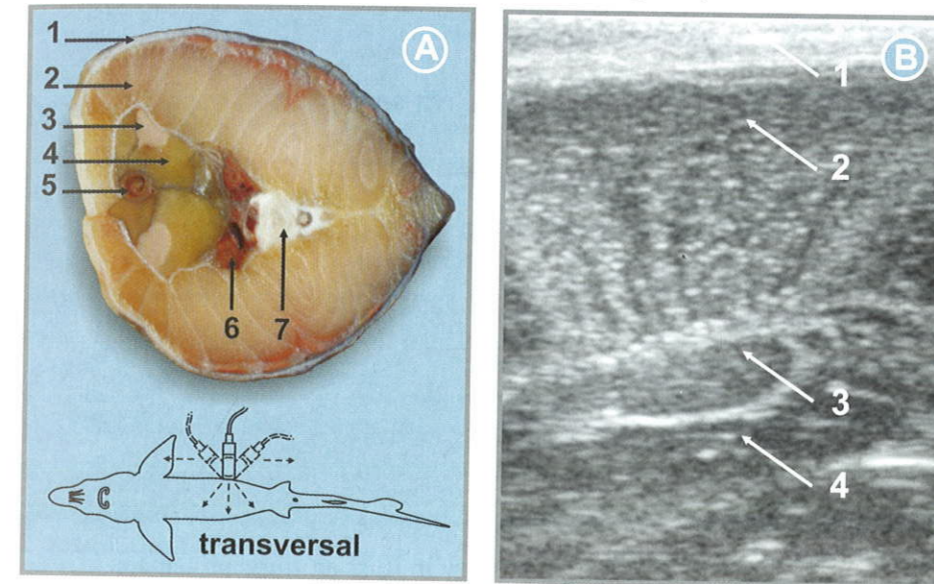


Fig. 3.8 View of organs localization in the body cavity of the male Siberian sturgeon: A – dissected transverse view; B – transverse ultrasound image (1 – skin and subcutaneous tissue; 2 – muscle fiber; 3 – gonad; 4 – fat).

Skin

The skin, adipose layer, muscular tissue and serous tunic and abdominal cavity are visualized in the same way as at the frontal scanning.

Gonads

The testicular tissue has an oval and almond-like shape enclosed within clear hyperechoic borderline with internal echouniform structure and is positioned in contrast to females immediately under muscular tissue. At the stage II of gonads maturity, the generative part is surrounded partially (II, II-semifatty, II-III) or completely (II fatty) is surrounded by fat tissue, which looks on the screen of monitor like a hypoechoic (dark, almost black) zone.

Ovarian tissue (region of mixed echogenicity) does not bound to the muscles, having no distinct margins. At some stages this part can be separated from the muscular tissue by hyperechoic fat part (Fig. 3.9).

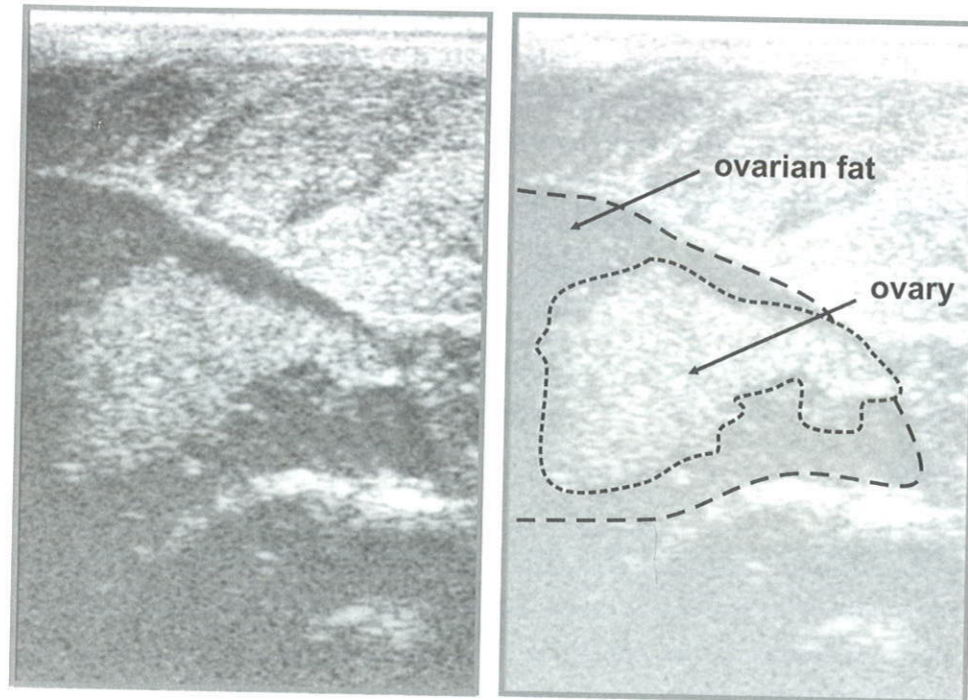


Fig. 3.9 Transverse ultrasound image of ovary in Russian sturgeon female.

Intestine

The intestine appears on the ultrasound image in a rounded shape structure with the clear boundaries, that comprises several layers of the different echogenicity.

Chapter 4 Early Sexing and Staging Maturity of Sturgeons by Using Non-invasive Express Ultrasound Technique

4.1 Onset of anatomical differentiation of gonads

To describe maturity stages in gonads of sturgeons we have used the maturity scale, developed by Trusov (1972) for Russian sturgeon.

The presented below peculiarities of different developmental stages of the testes and ovaries in sturgeons are important for the analysis of ultrasound images of sturgeon gonads.

The major part of ultrasound images has been obtained using ultrasound scanning system Mindray-DP 6600, while others using system My Sono-201 we used earlier (Chebanov et al., 2004). In the latter case the scanner type is indicates in figure captions.

The sex of sturgeons at first stages of gonad development could hardly be visually identified, due to gonad appearance as thin pink and yellow strips both in males and females (Persov, 1975).

A longitudinal fissure appearance at the lateral side of the gonad is one of the main differential diagnosis of the ovaries of stage I females, as distinct from the testis of stage I males. This fissure is more evident at the caudal part of the gonad. Generative cells of the ovary tend to group at the fissure area. Later on, formation of transverse ovigerous lamellae begins extending longwise through the fissure.

Individual oocytes at initial protoplasmatic growth phases are discernable in histological samples of gonads at maturity stage I.

As reported in Zubova (1971), the lack of longitudinal fissure in juveniles, when it obvious in most fish of the same generation, serves as an indirect sign of gonads development in the direction of the testis, which starts from the seminiferous tubules formation.

4.2 Analysis of ultrasound images of different stage of testes development

4.2.1 Male maturity stage I (M1)

The testes appear as thin strips of white and grey to light pink colour (Fig. 4.1). At the onset of the stage, they are composed primarily of connective tissue, while at the stage completion the testis reaches 5-7 mm in width. The fat tissue of the testis practically is not evident, while the testicular tissue has milky white colour.

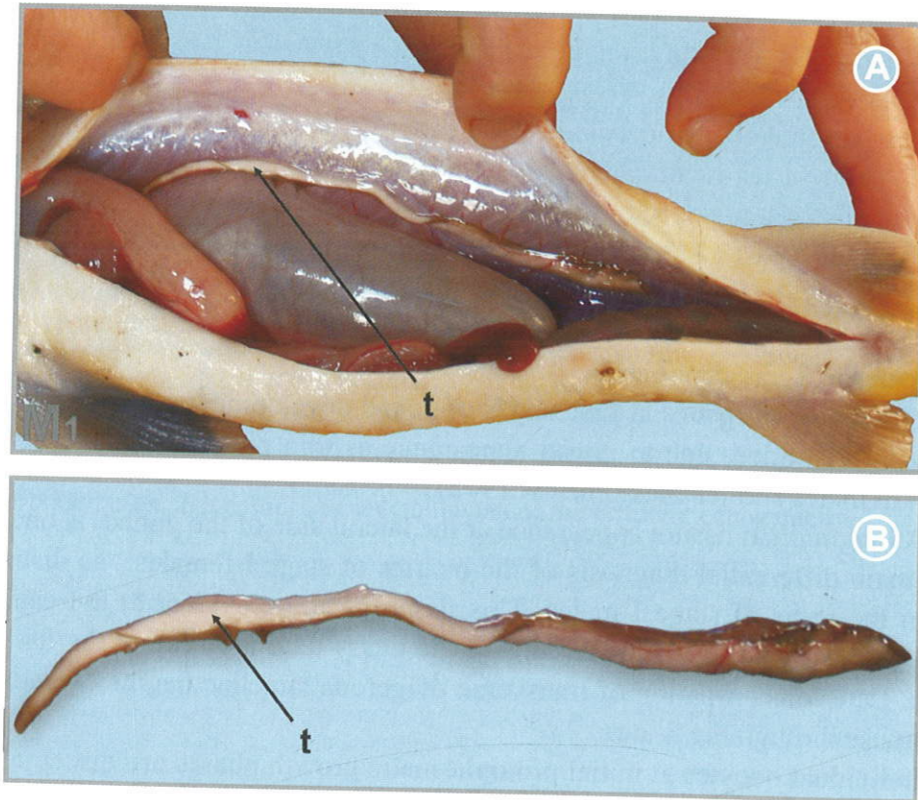


Fig. 4.1 Testes at maturity stage I (M1) in male sterlet: age – 1 years; weight – 0.25 kg; length – (L/l) 41.0/33.0 cm. Testis (t): width – 0.4 cm. A – localization of testes; B – view of testes (t).

At ultrasound scanning of males (Fig. 4.2), testicular tissue are not visible due to its small size.

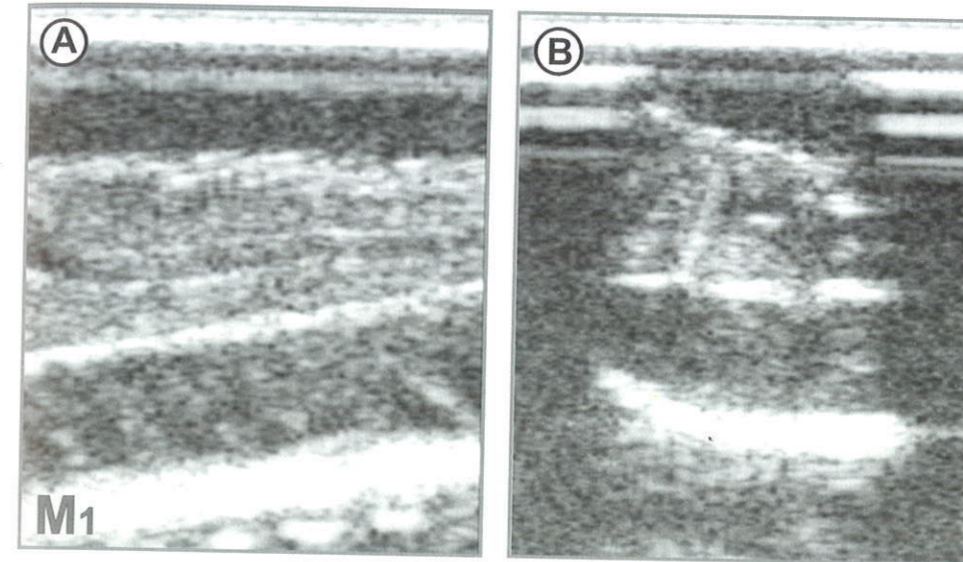


Fig. 4.2 Echogram of testes in sterlet male at maturity stage I: A – frontal section; B – transverse section.

4.2.2 Male maturity stage II (M2)

The testes at stage II are well discernable, typically having white or pink-white colour (Fig. 4.3). The width of the testicular tissue in fish at first maturation is ranged from 0.3 to 0.6 cm, while in re-maturing – from 1.0 to 1.5 cm. The overall width (with the fat tissue) is 1.5 cm and up to 3.5 cm at first and recurrent maturity respectively. These differences enable identification of males at recurrent maturity.

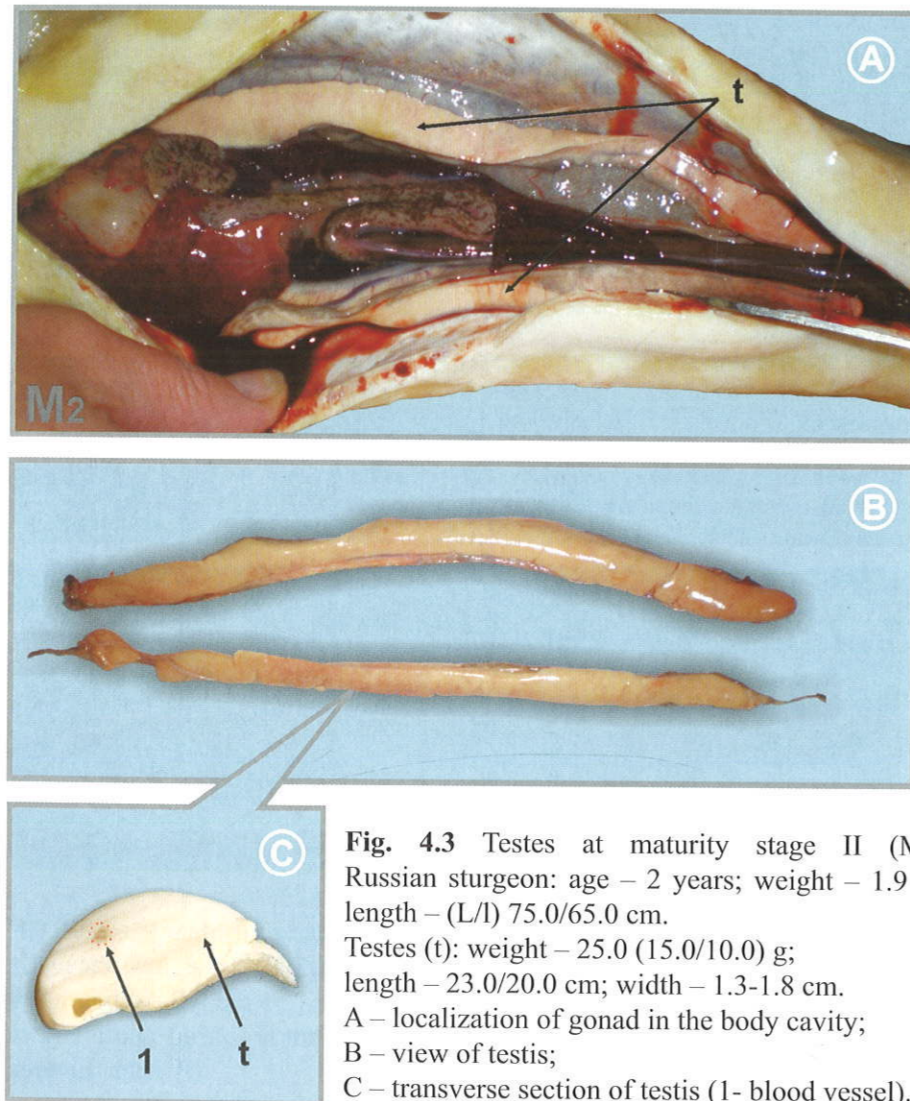


Fig. 4.3 Testes at maturity stage II (M2). Russian sturgeon: age – 2 years; weight – 1.9 kg; length – (L/l) 75.0/65.0 cm. Testes (t): weight – 25.0 (15.0/10.0) g; length – 23.0/20.0 cm; width – 1.3-1.8 cm. A – localization of gonad in the body cavity; B – view of testis; C – transverse section of testis (1- blood vessel).

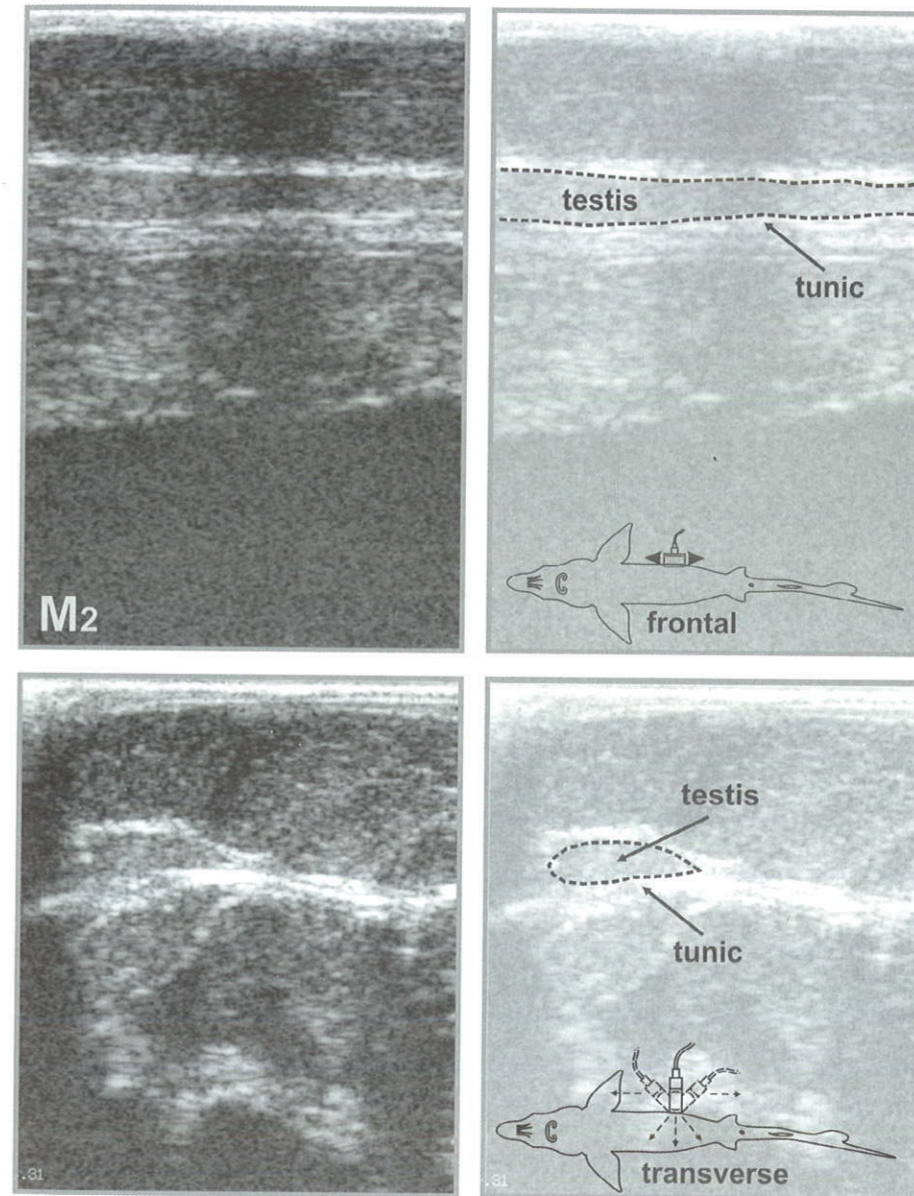


Fig. 4.4 Ultrasound image of frontal and transverse sections of testes in Russian sturgeon male at maturity stage II (M2).

Starting from maturity stage II, testicular tissue can be easily visible at frontal and transverse sections (Fig. 4.4). The testicular part is hyperechoic and have distinct margins. The fat part is under- or slightly developed from the medial side and practically not visual. The margins of the gonad is smoothly curved, while the bright hyperechoic tunic of the testis is well visual.

4.2.3 Male maturity stage II semi-fatty (M2sf)

Fat accumulation starts from the medial side and gradually spreads to the lateral side (Fig. 4.5). The state when testicular tissue is covered by fat to one half of its width (and can be visual only from the lateral side) is considered as stage II semi-fatty. Its width is ranged from 0.2 to 2.5 cm (including 1.0-5.0 cm fat), colour varies from pinkish to white.

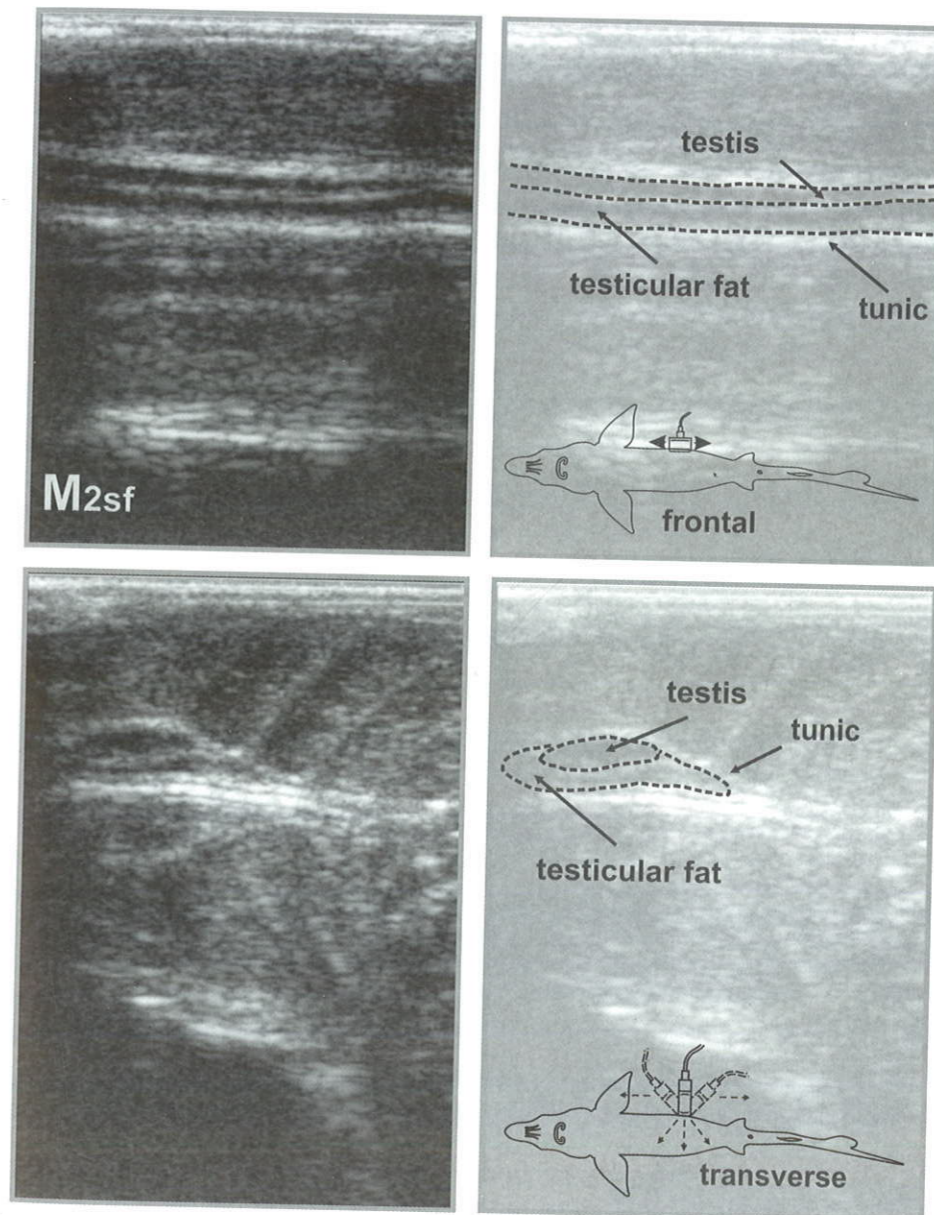
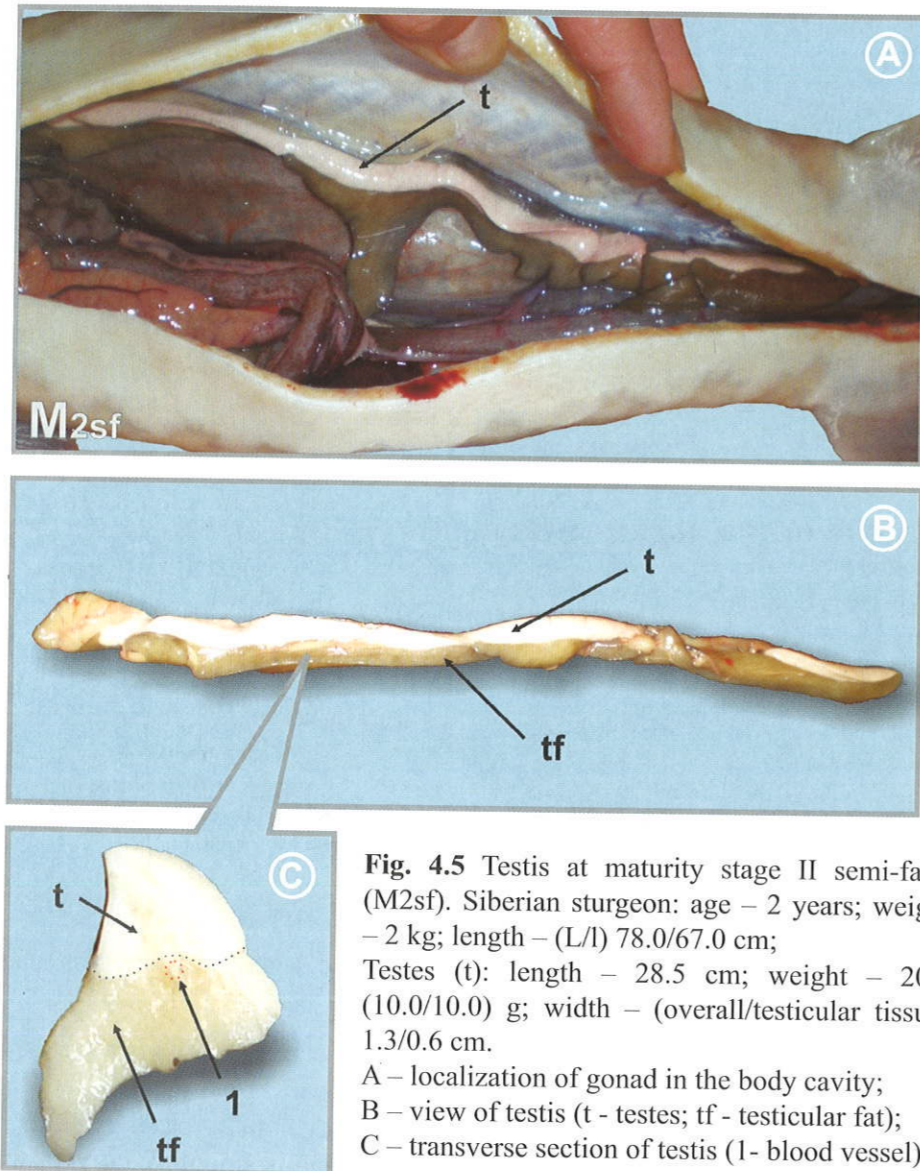


Fig. 4.6 Ultrasound image of frontal and transverse sections of Siberian sturgeon male at maturity stage II semi-fatty (M2sf).

At developmental stages II semi-fatty and fat, the testicular tissue exhibits slight increase. The overall volume of gonad expands to an account of fat accumulation. Therefore, the colour of the testicular and fat tissues on the echogram is practically identical. The testicular tissue at stage M2sf (Fig. 4.6) is hypochoic and appears on the screen as dark regions, divided by light strip – boundary between the fat and germinal tissues.

4.2.4 Male maturity stage II fatty (M2f)

At this stage fat deposition in the testes is associated with its accumulation in the muscles. Fat accumulation in the body cavity appears as thin strips, those being combined into a solid mass with enlarged width and depth. In the process of development from stage II to stage II fatty, the weight of the testes exhibit 5-10-folds increase (fat associated). The testes width ranges from 1.3 to 6.5 cm, while weight of fat – from 80 to 95% of the total gonad weight. Visually, the testicular tissue is completely covered by fat (Fig. 4.7).

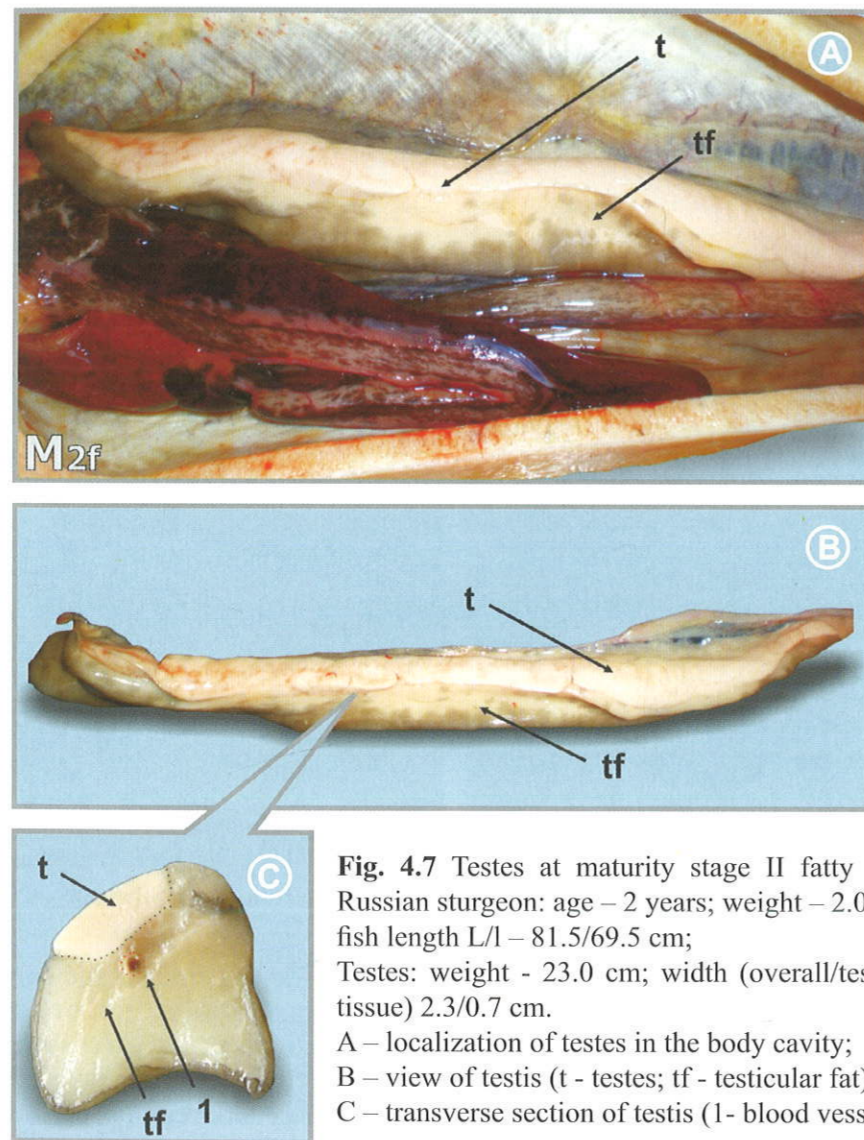


Fig. 4.7 Testes at maturity stage II fatty (M2f). Russian sturgeon: age – 2 years; weight – 2.0 kg; fish length L/l – 81.5/69.5 cm; Testes: weight - 23.0 cm; width (overall/testicular tissue) 2.3/0.7 cm. A – localization of testes in the body cavity; B – view of testis (t - testes; tf - testicular fat); C – transverse section of testis (1 - blood vessel).

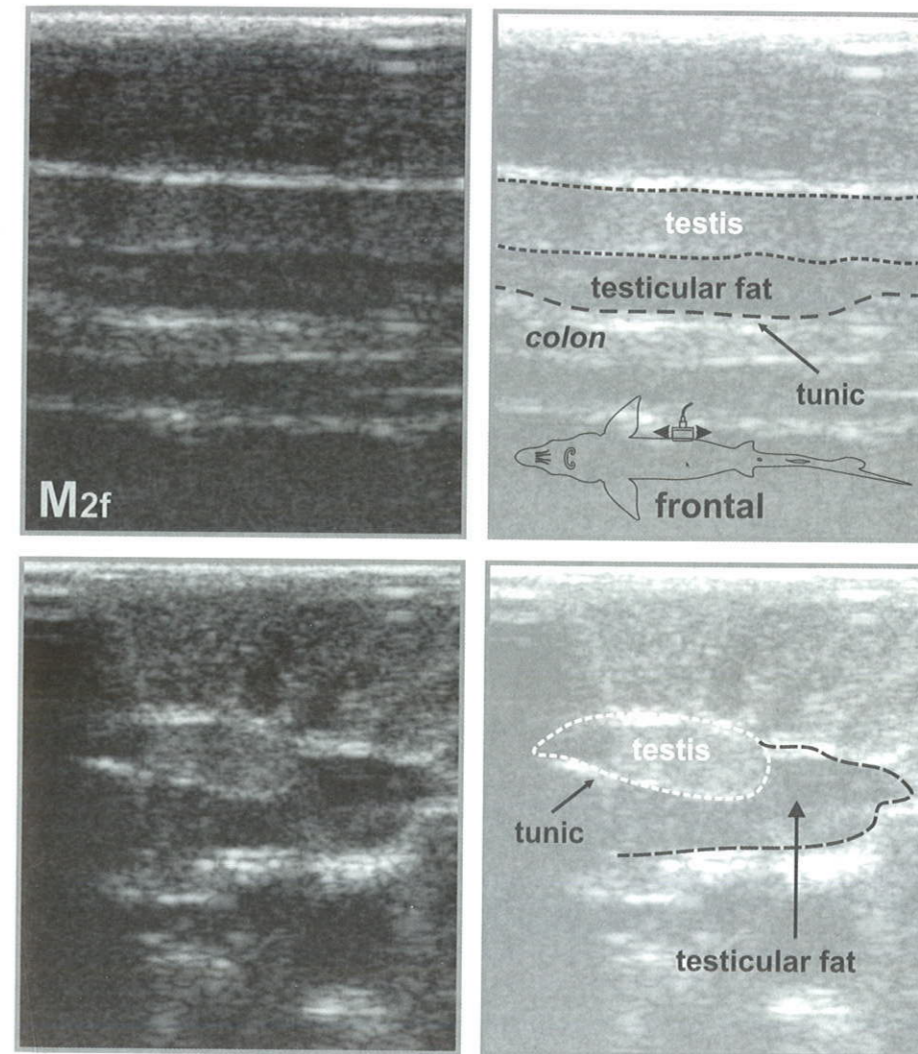


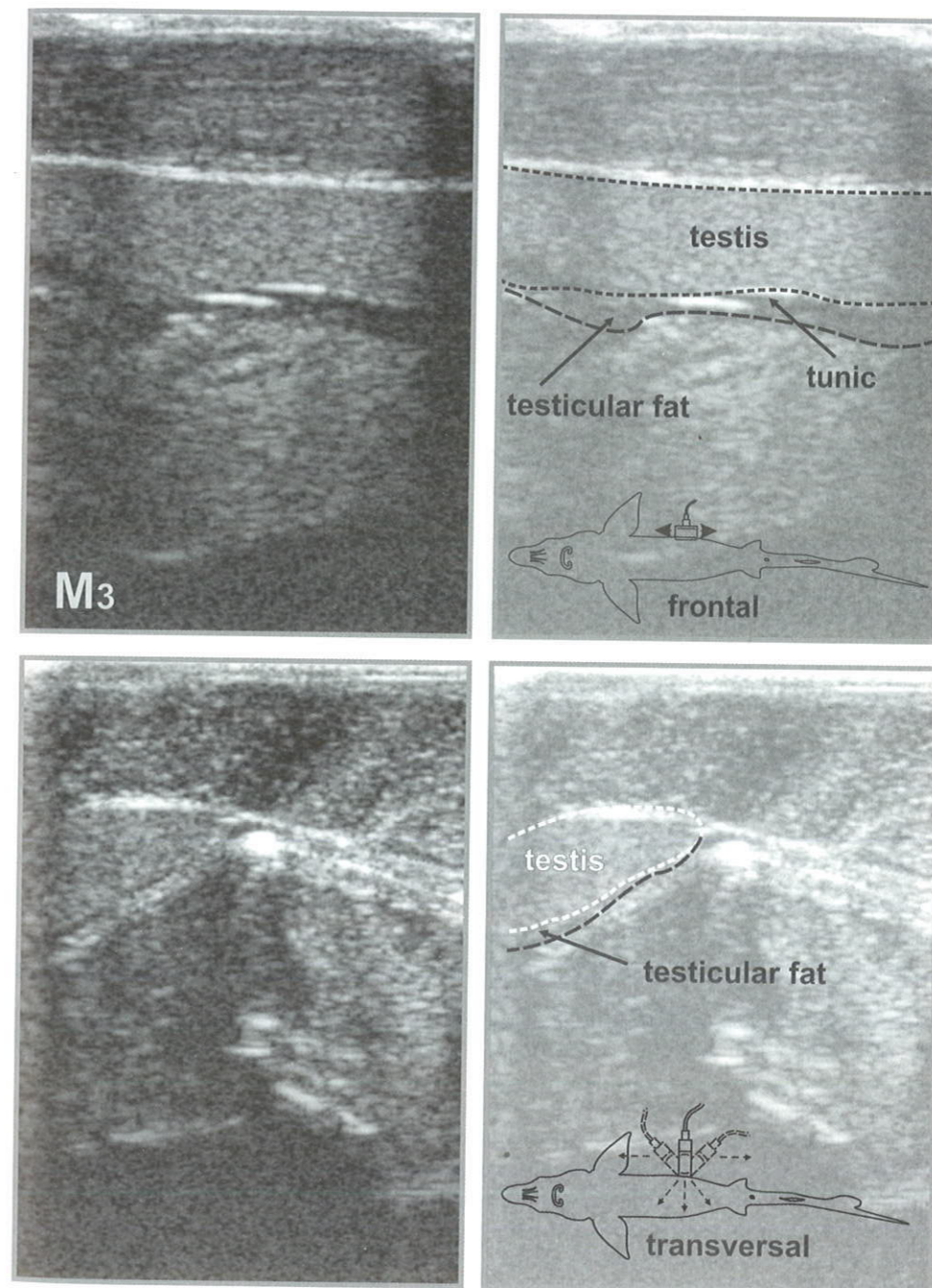
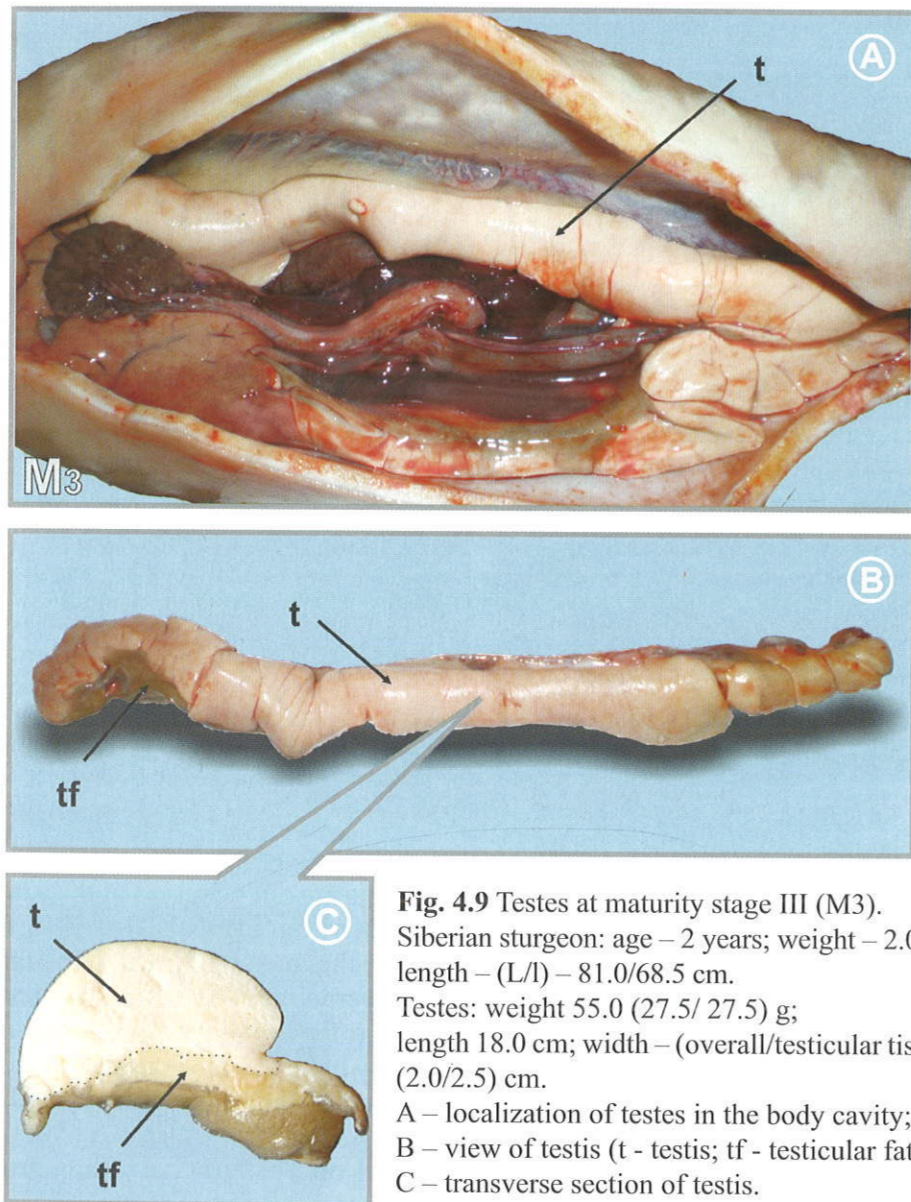
Fig. 4.8 Ultrasound images of frontal and transverse sections of Russian sturgeon male at maturity stage II fatty (M2f).

Any considerable changes in spermatogenesis are not occurred at this stage of testes development. Therefore, echogenicity of the testicular tissue in the gonad tends to be low, but slightly higher than that at stage II and semi-fatty stage II. Hence, the testis becomes well discernable. The testicular tissue appears as homogeneous fine-grained structure (of grey colour on echograms), separated from the fat one (hypoechoic, dark) by hyperechoic boundary, visual as a bright white line. The testis on the transverse section is tightly bound to the lateral muscles (Fig. 4.8).

Males can be easily and reliably identified on echograms starting from maturity stage II.

4.2.5 Male maturity stage III (M3)

This stage of a very short duration. Fat is almost completely being used for sexual cells (spermagonia and spermatocytes) formation. The testicular portion of the gonad exhibits considerable increase (Fig. 4.9). Blood vessels netting is well visualized on the surface of testis. At this, hyperaemia of the testis is observed, as a result of high level of blood circulation at this stage.



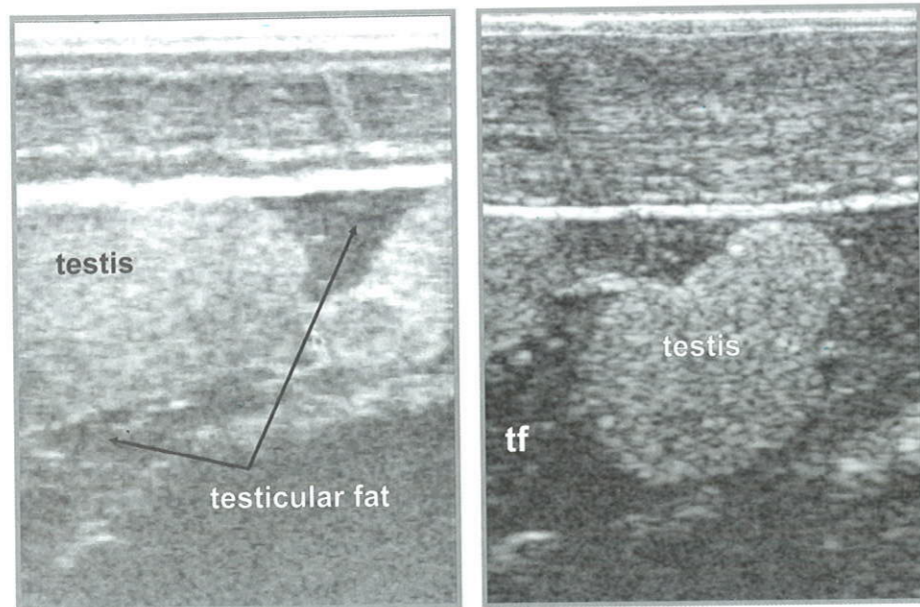


Fig 4.11 Ultrasound images of frontal sections of Siberian sturgeon male at maturity stage III (M3) after overwintering.

The testes appear on the echogram (Fig. 4.10) as “crumpled” or “lobular” with curved margins or rounded hyperechoic homogeneous structures, resulting from high rate of testicular development at the period of about to complete cessation of linear body growth (typically during fish overwintering).

At maturity stage III (M3), echogenicity of the testicular tissue exhibits considerable increase (Fig. 4.11) The testes appear on echograms as a homogeneous structure of light grey (in some cases white) colour with distinct hyperechoic margins. In some cases, two clear hyperechoic lines – gonad margins and linings of peritoneum are well discernable. The fat on the lateral side is completely absent, remaining in small quantity on the medial side, looking on echograms like a thin hypoechoic strip.

4.2.6 Male maturity stage IV (M4)

This stage is characterized by completion of the spermatogenesis process. The testes become light, almost milky in colour and being almost completely deprived of fat (Fig. 4.12). The surface of testis in early stage get brilliant “as if it is covered with a thin layer of wax” (Trusov, 1972).

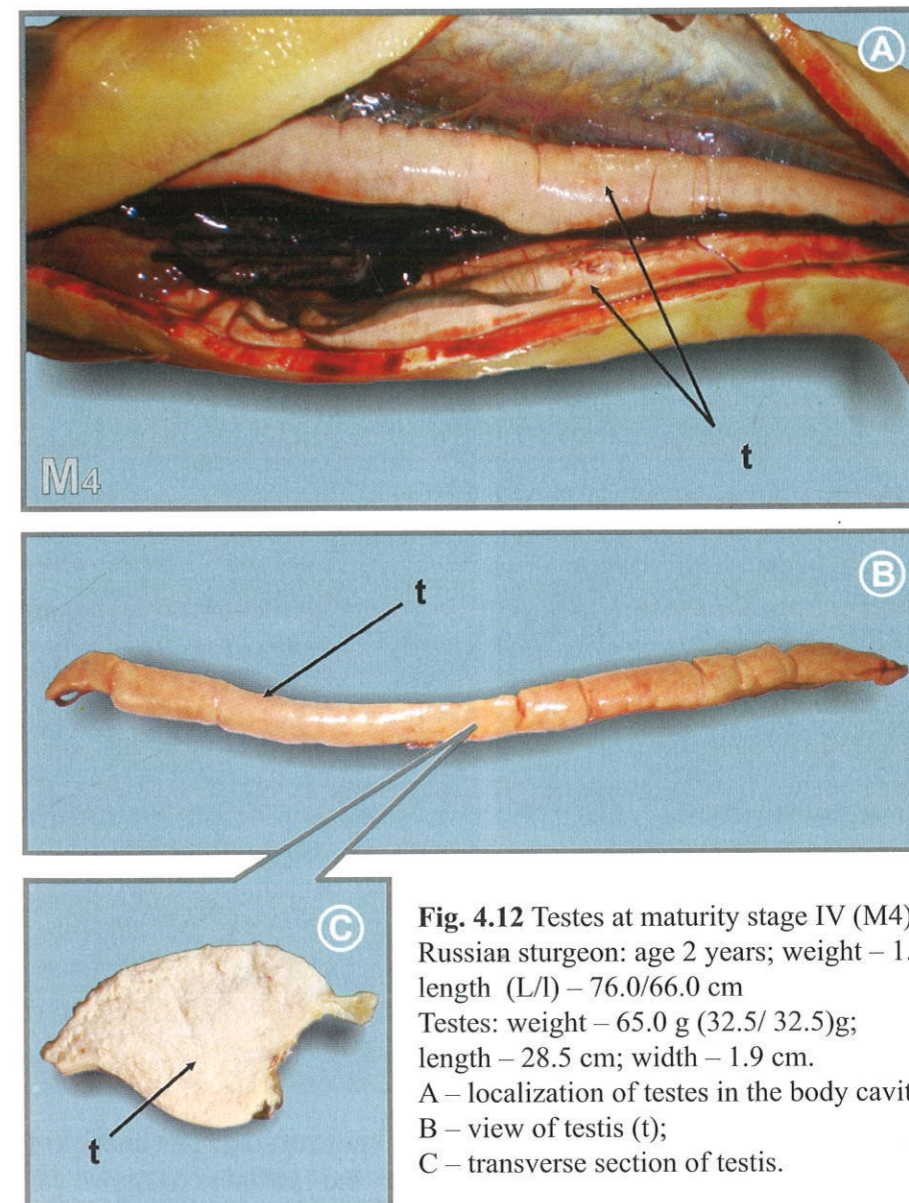


Fig. 4.12 Testes at maturity stage IV (M4) of Russian sturgeon: age 2 years; weight – 1.9 kg; length (L/l) – 76.0/66.0 cm; Testes: weight – 65.0 g (32.5/ 32.5)g; length – 28.5 cm; width – 1.9 cm. A – localization of testes in the body cavity; B – view of testis (t); C – transverse section of testis.

On echogram (Fig. 4.13) the testes at stage IV appear as a bright hyperechoic fine-grained homogeneous structure with clear margins and well-defined tunics, that are well discernable both in the frontal and transverse sections.

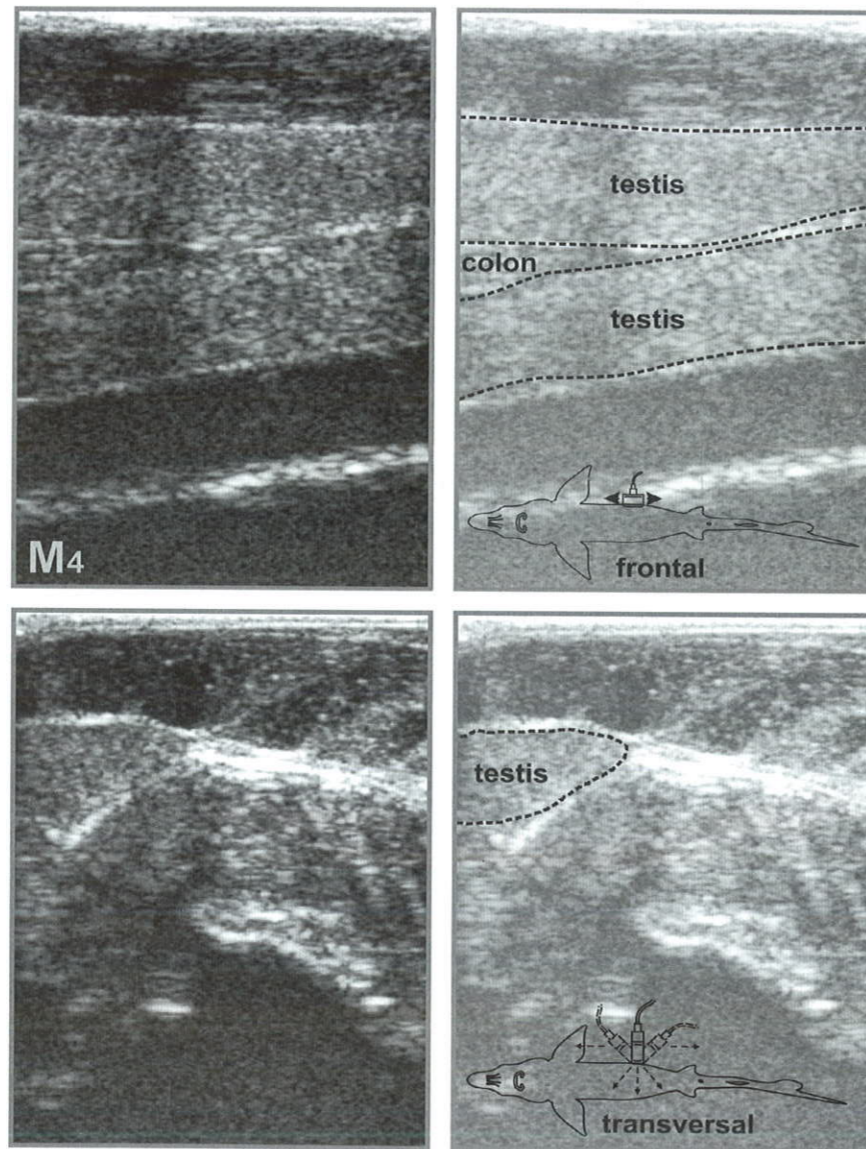


Fig. 4.13 Ultrasound images of frontal and transverse sections of Russian sturgeon male at maturity stage IV (M4).

Hyperechogenicity of testis reaches its maximum at stage IV (image colour is close to white). The ripe male maturity status and readiness to spawn can be assessed by the brightness of the testis image.

4.2.7 Male maturity stage V (M5)

During the spawning period, the echogenicity of testicular tissue exhibits some decrease (became dark) as a result of seminal fluid formation (Fig. 4.14). The medial margin of testis becomes “fuzzy” and could not be visual in some cases.

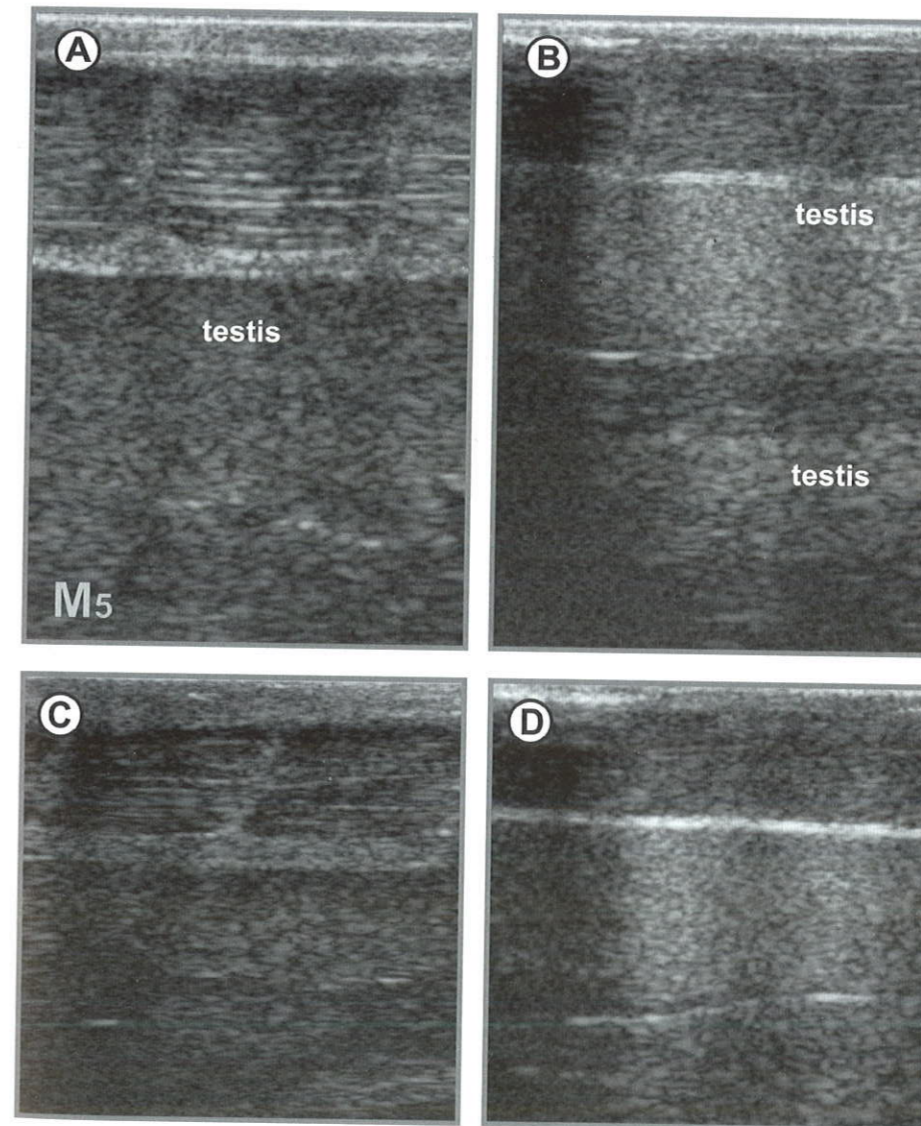


Fig. 4.14 Ultrasound images of frontal sections sturgeon males during spawning (M5): beluga (A), stellate sturgeon (B), Russian sturgeon (C) and ship sturgeon (D). Second gonad with completely diffused margins is evident.

4.3 Analysis of ultrasound images of ovaries at different maturity stages

4.3.1 Female maturity stage I (F1)

Ovarian developmental at stage I in sturgeon females is characterized by appearance of longitudinal fissure on the lateral side of gonad, that is more clear on the caudal part (Fig. 4.15). Generative cells in females are clustered in the area of the fissure, later the formation of transverse ovigerous lamellae begins along all the gonad length.

Individual oocytes at initial stages of protoplasmatic growth are found on histological samples of females at maturity stage I.

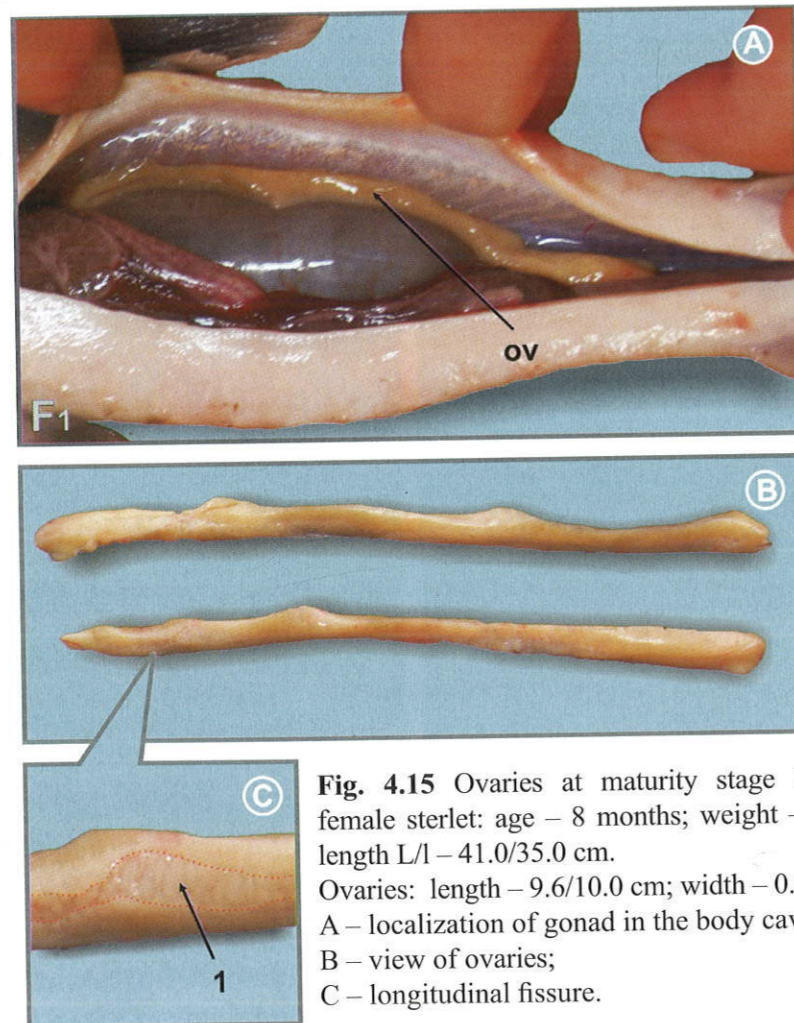


Fig. 4.15 Ovaries at maturity stage I (F1) in female sterlet: age – 8 months; weight – 0.22 kg; length L/I – 41.0/35.0 cm. Ovaries: length – 9.6/10.0 cm; width – 0.4 cm
A – localization of gonad in the body cavity;
B – view of ovaries;
C – longitudinal fissure.

On the image of ovaries at maturity stage I (Fig. 4.16), as distinct from testes, the germinal portion of gonad is well-defined. On the frontal ultrasound image, ovary appears as a fine-grained moderately echogenous structure of irregular form, deprived of tunic. On the transverse image, both ovaries are well evident, but are not of significant size.

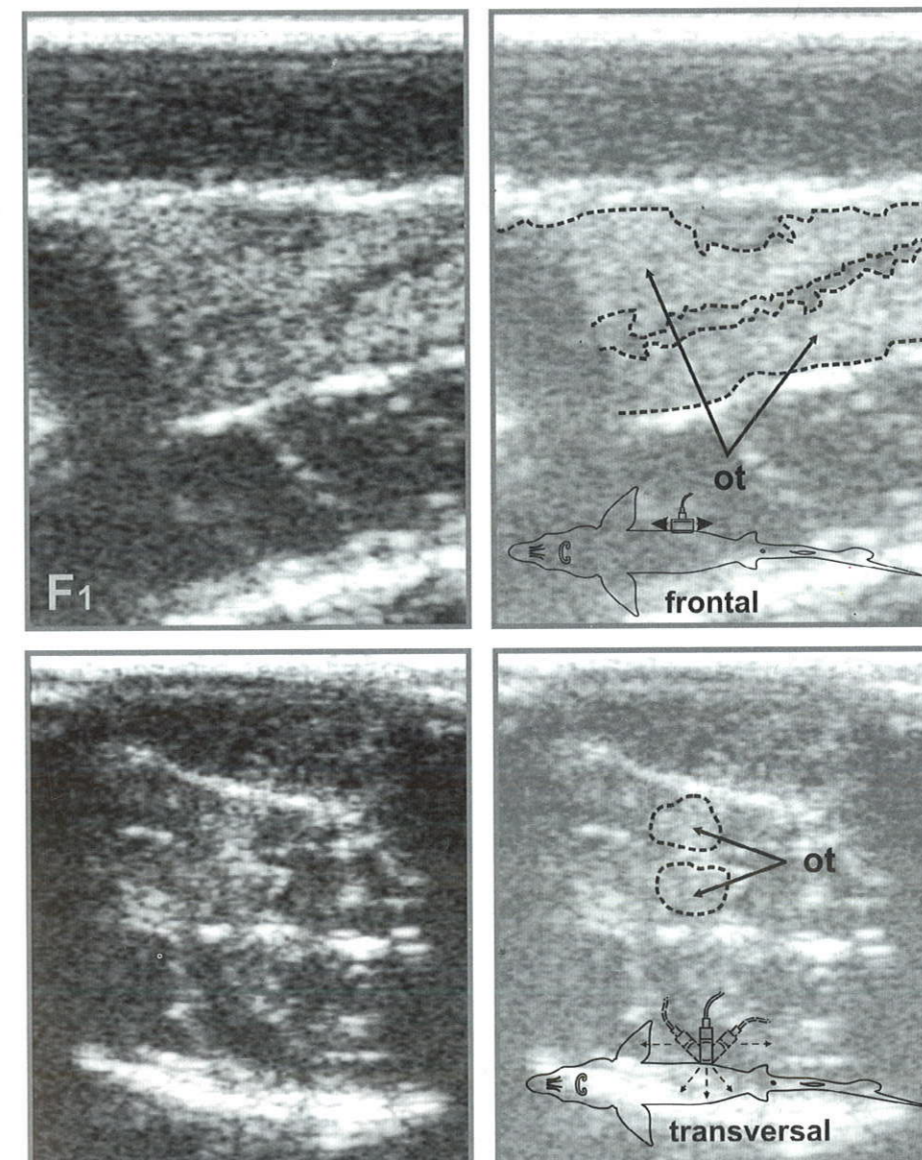


Fig. 4.16 Ultrasound images of frontal and transverse section of ovaries in female sterlet at maturity stage I (F1).

The prevailing of the ovarian tissue of increased echogenicity in gonad causes failure in identification of females at maturity stage I (Fig. 4.17). To avoid cases of improper sex identification, the special attention should be paid to the character of gonad margin and lack of tunic (Fig 4.18), that can be discernable on ovaries echograms by indistinct medial margin of the gonads.

Late maturity stage I (F1) may be easily determined in the dynamic "Cine mode" by prior moving of the transducer from pelvic to a pectoral fin (at frontal scanning), when the ovarian tissue appears as "flowing" structure of high echogenicity with uneven margins without tunics in anechoic fat.

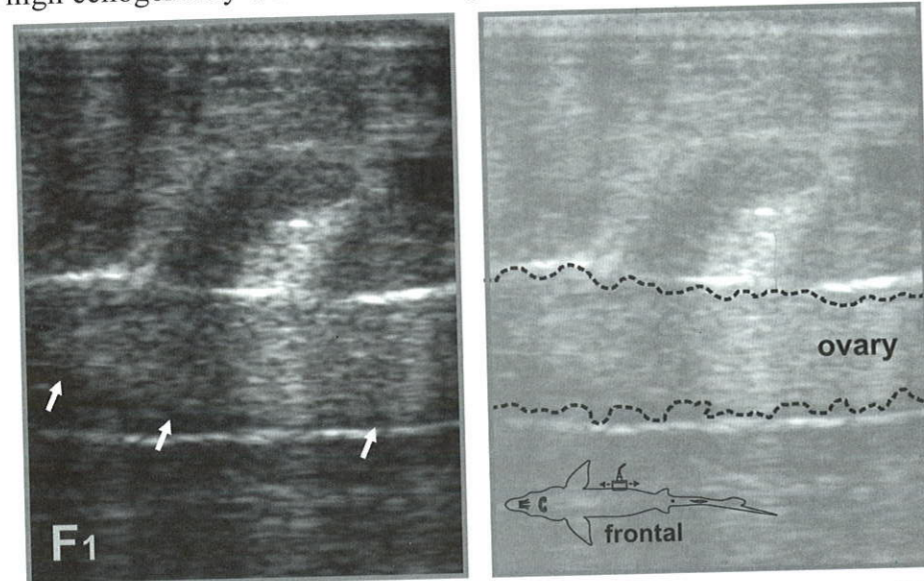


Fig. 4.17 Ultrasound frontal images of ovaries in Russian sturgeon at maturity stage I (F1).

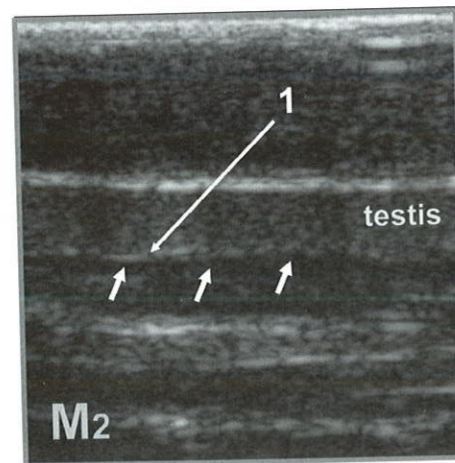


Fig. 4.18 Frontal ultrasound images of testes (1 – tunic) in Russian sturgeon at maturity stage II (M2).

Note, that stage I (F1) can be observed only in immature individuals (once during the whole life cycle). The ovaries in mature fish after spawning transit to maturity stage II.

4.3.1 Female maturity stage II (F2)

At the beginning of maturity stage II, the ovaries possess little fat. At this stage (F2), fat accumulates in the germinal portion of gonad, while in males it accumulates beyond the testicular one (Fig. 4.19).

"Brain like" (Bruch et al., 2001) folds (ovigerous lamellae) are well notable from the lateral part of ovary. The colour of the ovaries varies from pink and white to yellow and pink (Bahmani et al., 2005).

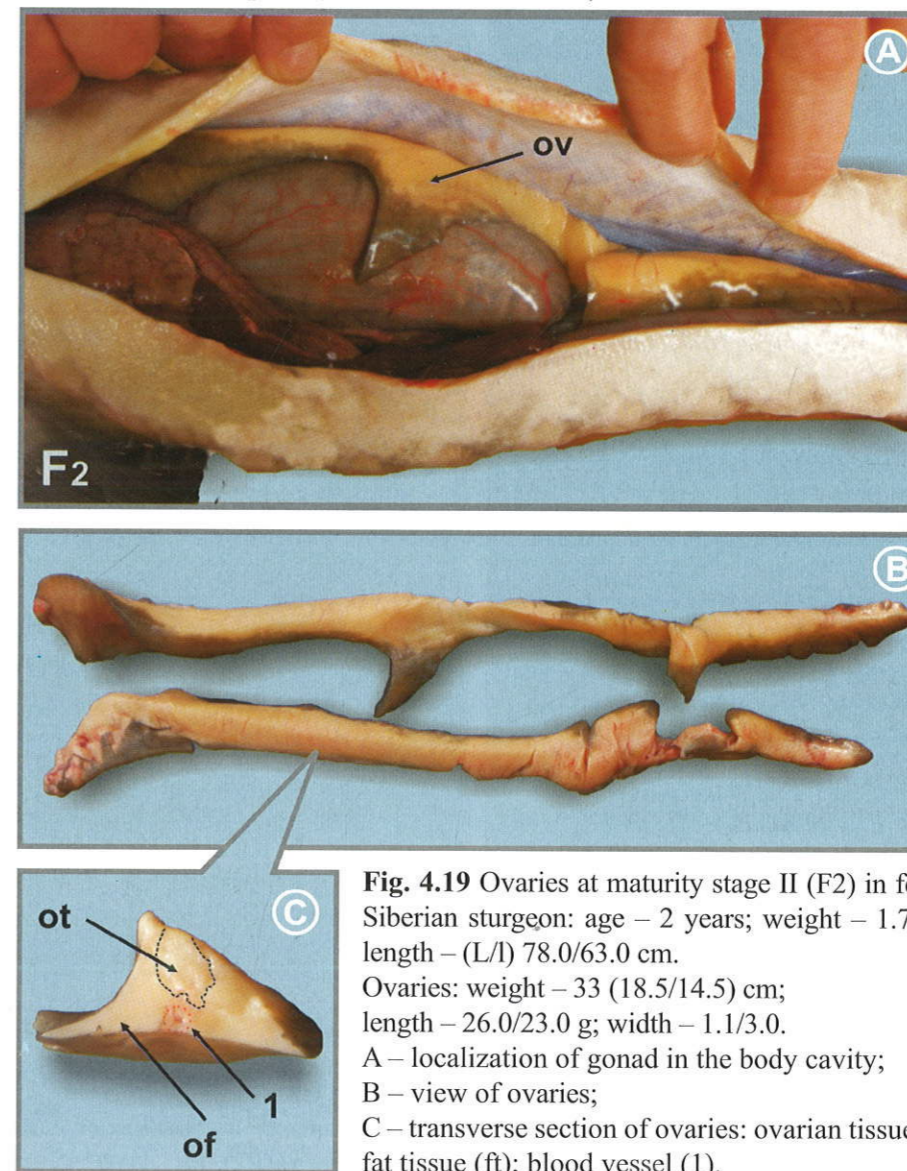


Fig. 4.19 Ovaries at maturity stage II (F2) in female Siberian sturgeon: age – 2 years; weight – 1.75 kg; length – (L/l) 78.0/63.0 cm. Ovaries: weight – 33 (18.5/14.5) cm; length – 26.0/23.0 g; width – 1.1/3.0. A – localization of gonad in the body cavity; B – view of ovaries; C – transverse section of ovaries: ovarian tissue (ot); fat tissue (ft); blood vessel (1).

On ultrasound images the ovarian tissue (F2) looks like a grained “cloud-like” structure of mixed echogenicity with uneven boundaries without tunic. The fatty portion of ovary, both on frontal, and on transverse image is little and if visible in the form of the darker areas as distinct from the lighter ovarian tissue.

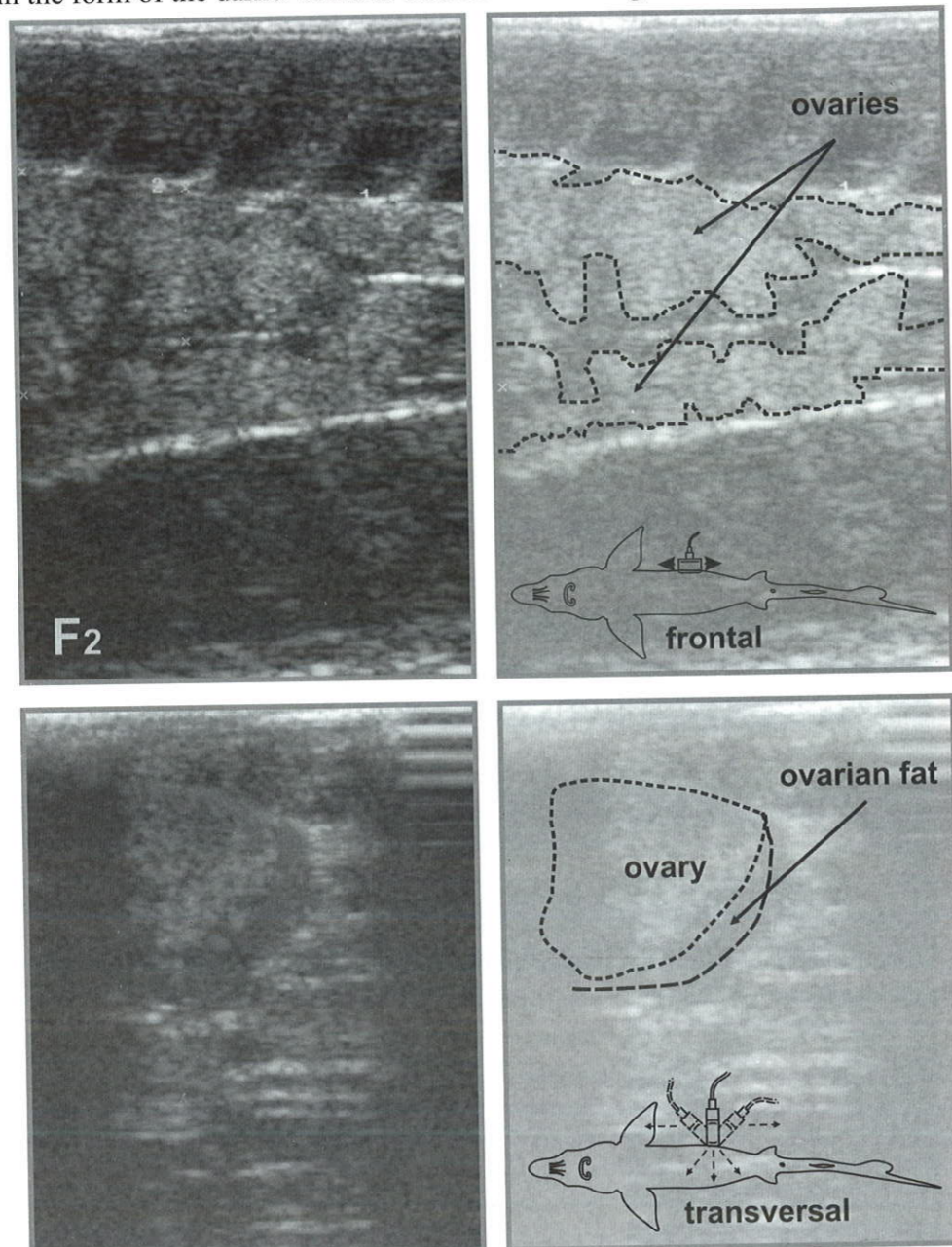


Fig. 4.20 Ultrasound images of ovaries at maturity stage II (F2).

Females at stage II (Fig. 4.20 & 4.21) can be easily identified on the frontal section with ovaries of the sufficient sizes (width 5-6 mm).

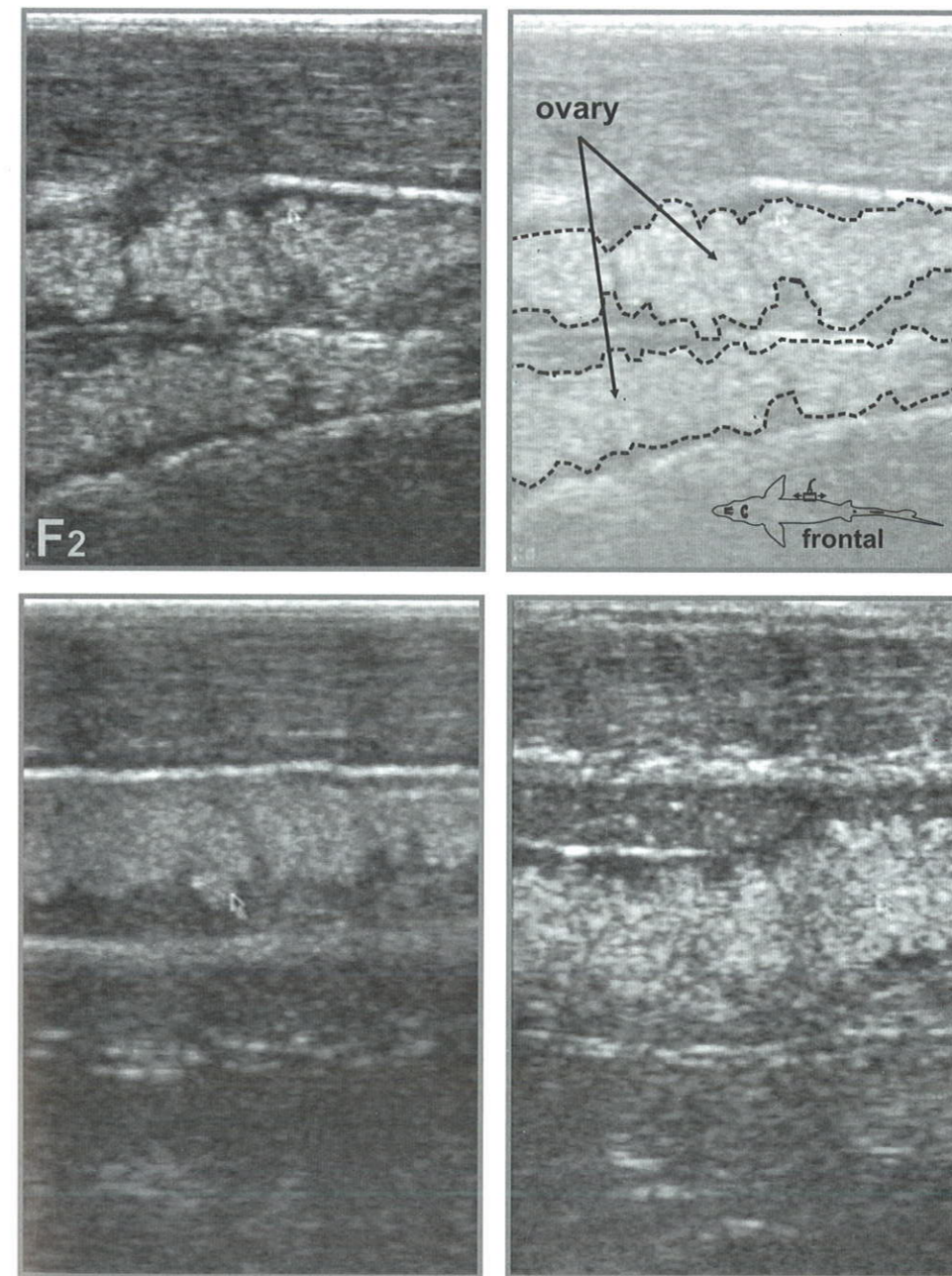


Fig. 4.21 Typical ultrasound images of female at maturity stage II (F2).

4.3.3 Female maturity stage II semi-fatty (F2sf)

Further development of the ovaries at maturity stage II semi-fatty (Fig. 4.22) is associated with fat deposition, that starts from the ovigerous lamellae (visually – the ovaries embedded in fat), and then continues on the medial and lateral sides.

Once the ovarian tissue is encompassed by fat more than half of its width (being visual along the entire lateral side), the ovaries transit to stage II semi-fatty (F2sf).

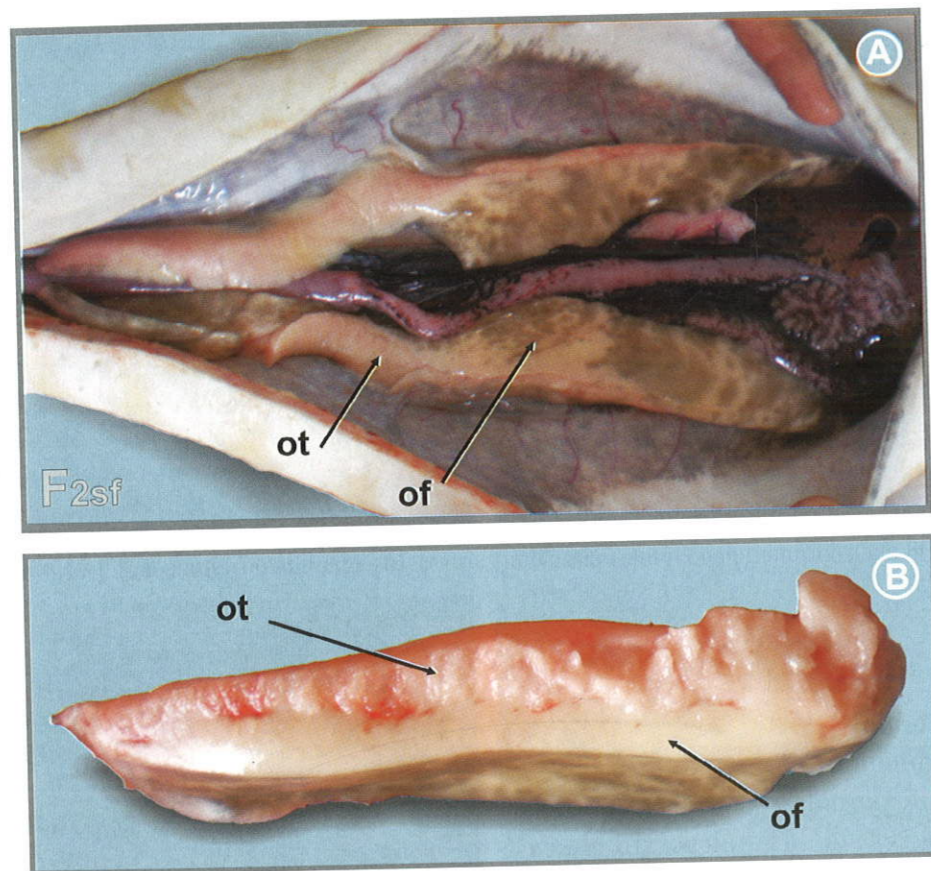


Fig. 4.22 Ovaries at maturity stage II semi-fatty (F2sf) ovaries in Russian sturgeon female:
 A – localization of ovaries in the body cavity;
 B – transverse section of ovaries: ovarian tissue (ot); fat tissue (ft).

On the ultrasound image (Fig. 4.23) single ovigerous lamellae appear as areas of higher echogenicity (of grey or light grey colour), alternates with hypoechoic (dark) fat regions. At this, ovigerous lamellae “grow” from lateral to media part of gonad.

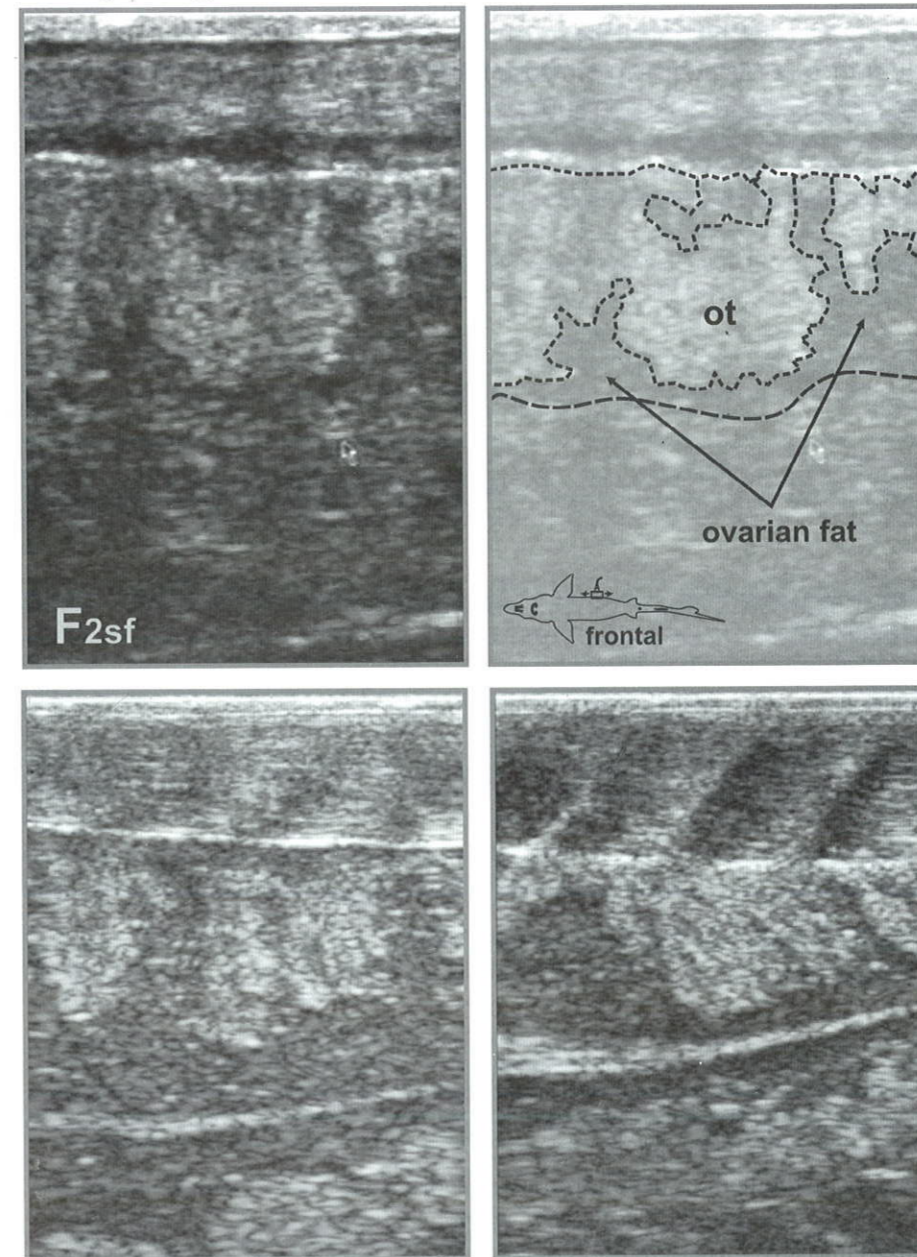


Fig. 4.23 Frontal ultrasound images of ovary at stage II semi-fatty (F2sf).

4.3.4 Female maturity stage II fatty (F2f)

At female maturity stage II fatty, ovaries accumulate fat on the lateral and medial sides to form a fat cover (Fig. 4.24). Fat folds, which cover almost all ovarian tissue, are evident at the lateral side.

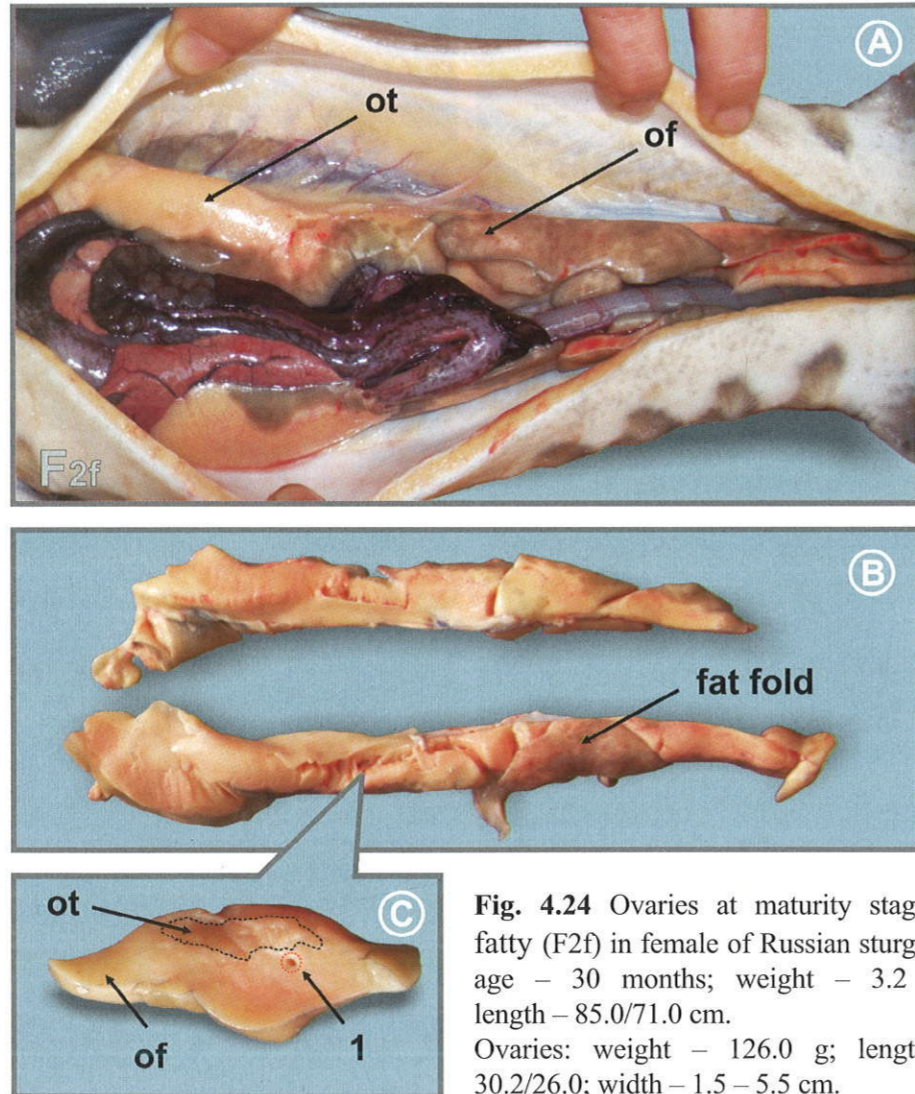


Fig. 4.24 Ovaries at maturity stage II fatty (F2f) in female of Russian sturgeon: age – 30 months; weight – 3.2 kg; length – 85.0/71.0 cm. Ovaries: weight – 126.0 g; length – 30.2/26.0; width – 1.5 – 5.5 cm.

A – localization of ovary in the body cavity;
 B – view of ovaries;
 C – transverse section of ovaries: ovarian tissue (ot); fat tissue (ft); blood vessel (1).

In contrast with previous maturity stages, the visual proportion of the ovarian and fat tissue on echograms is different (F2f). The ovarian tissue (light, of moderate echogenicity) is surrounded by fat both from the medial and lateral sides (dark anechoic regions). Dark anechoic fat layer is well discernable between muscles and gonads (Fig. 4.25).

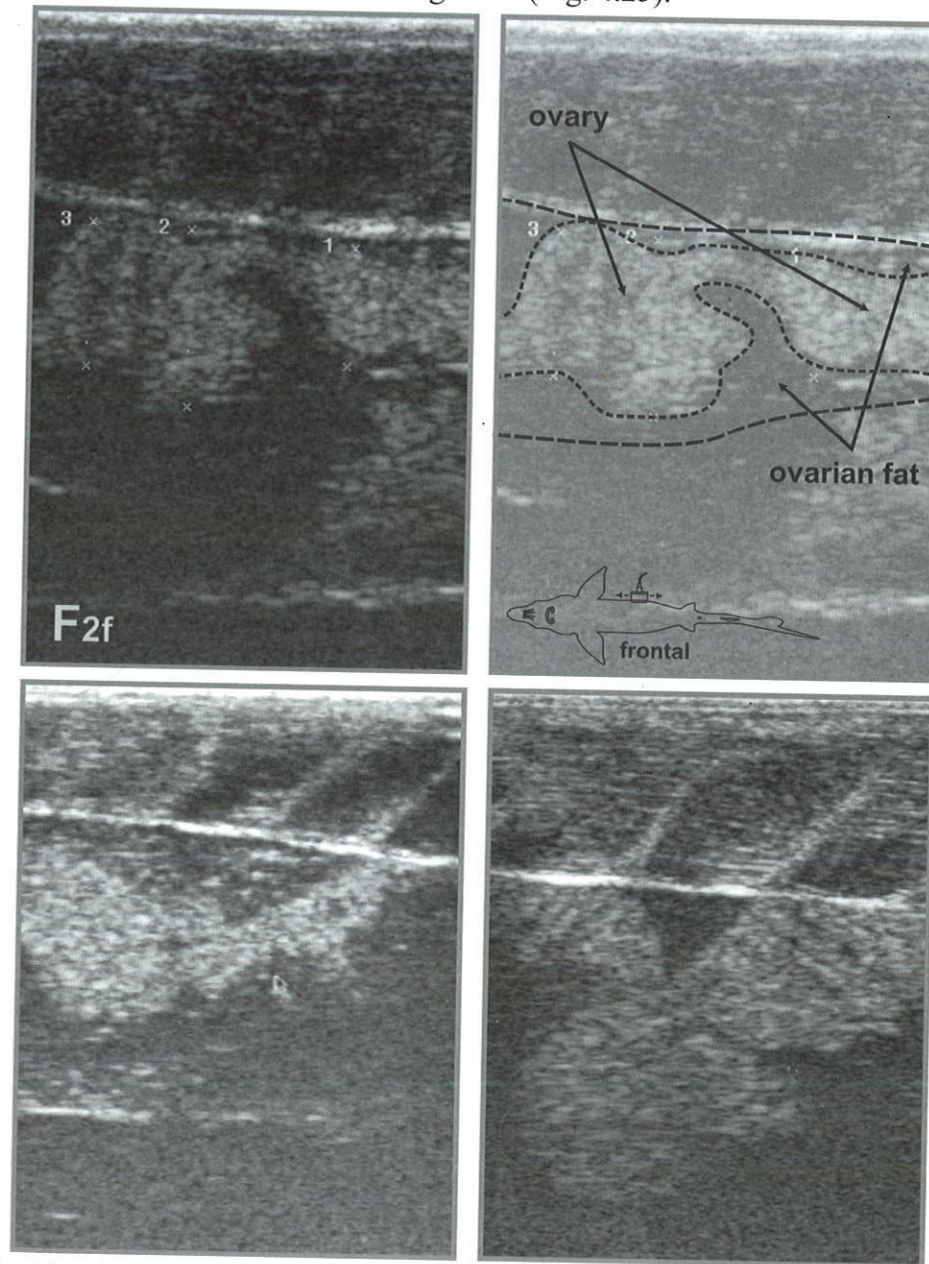


Fig. 4.25 Ultrasound images of frontal section of ovaries at maturity stage II fatty (F2f).

At transverse scanning (Fig. 4.26), the ovarian tissue (more light) is encompassed by the fat (more dark) tissue (more light), that is one of the most typical signs of echograms of females at maturity stage II fatty (F2f).

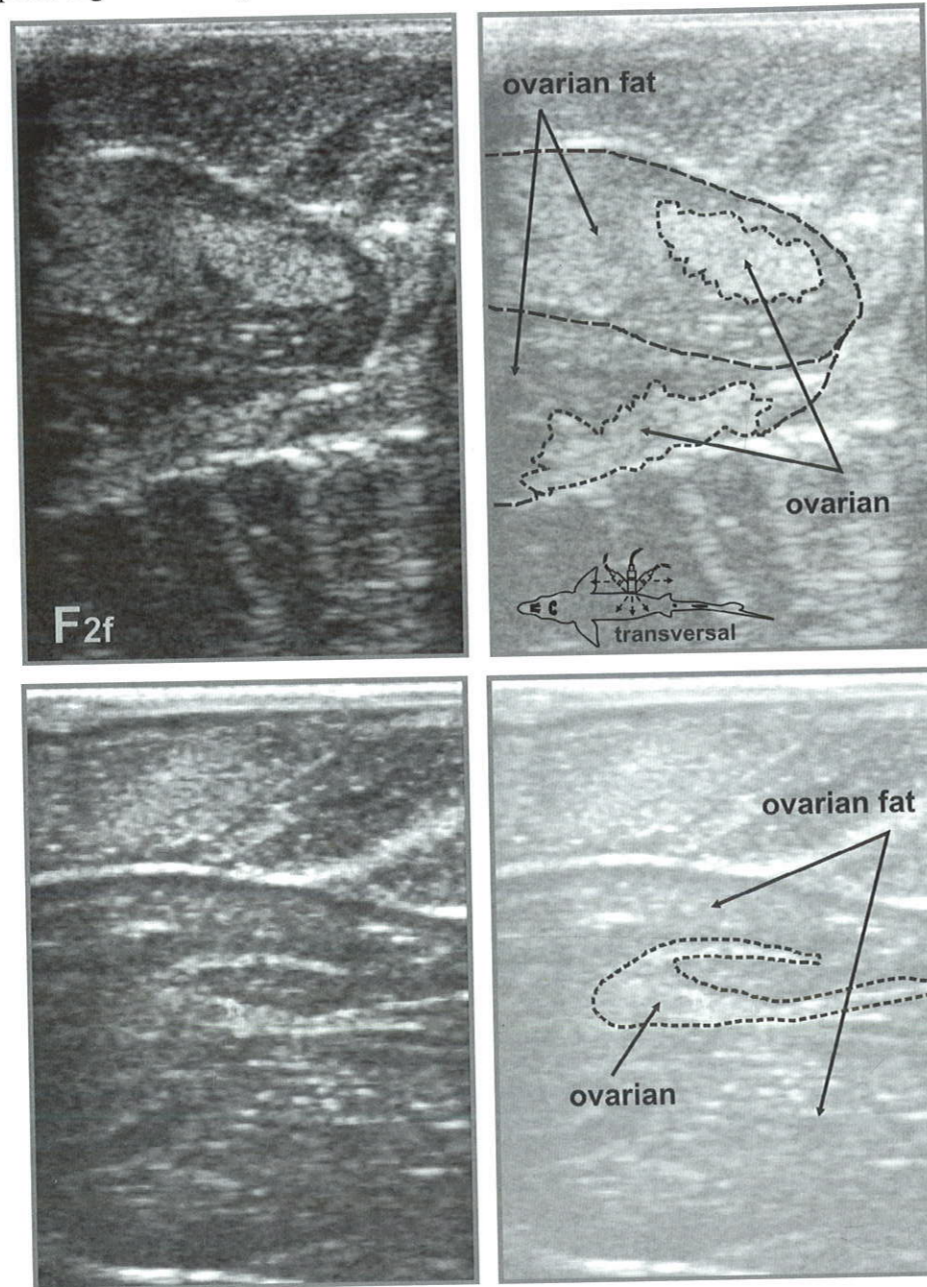


Fig. 4.26 Ultrasound image of transverse sections of ovaries at maturity stage II fatty (F2f).

4.3.5 Female maturity stage II-III (F2-3)

At the onset of vitellogenesis, the further maturation of the ovaries is associated with the trophoplasmatic growth of oocytes due to ongoing yolk synthesis. Gonads tend to possess less fat, the ovarian tissue becomes more evident (Fig. 4.27). The oocytes of senior generation (of diameter about 0.5 mm) protrude above the lateral part of the testis, and attain bright yellowish coloration associated with the fat droplets formation in cytoplasm.

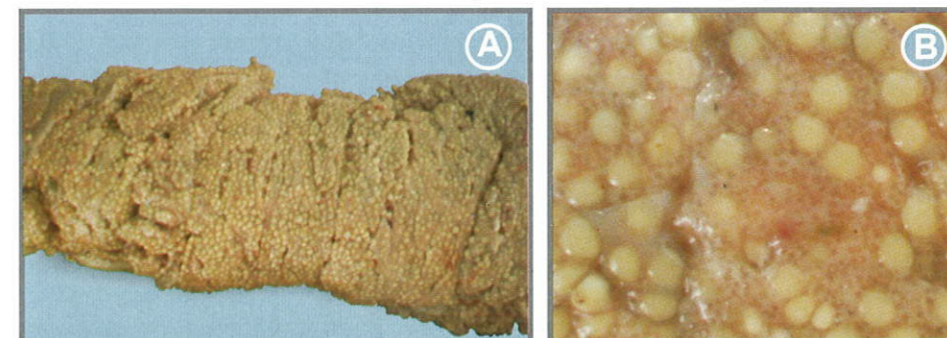


Fig. 4.27 View of ovary (A) at maturity stage II-III (F2-3). Zoomed view of oocyte of senior generation (B).

An ovary on the ultrasound image shows (Fig. 4.28 & 4.29) moderate echogenicity appearance (grey or light grey). Ovigerous lamellae “penetrate” the gonad body and appears as brachiate vertical structure (“coral-like” or “fringed” in shape), of higher echogenicity, spreading to the dark hypochoic region (the fat tissue).

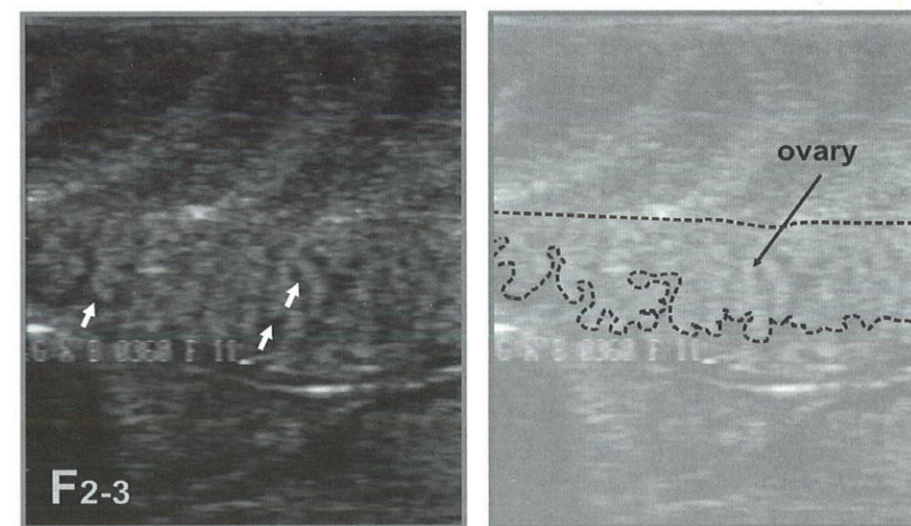
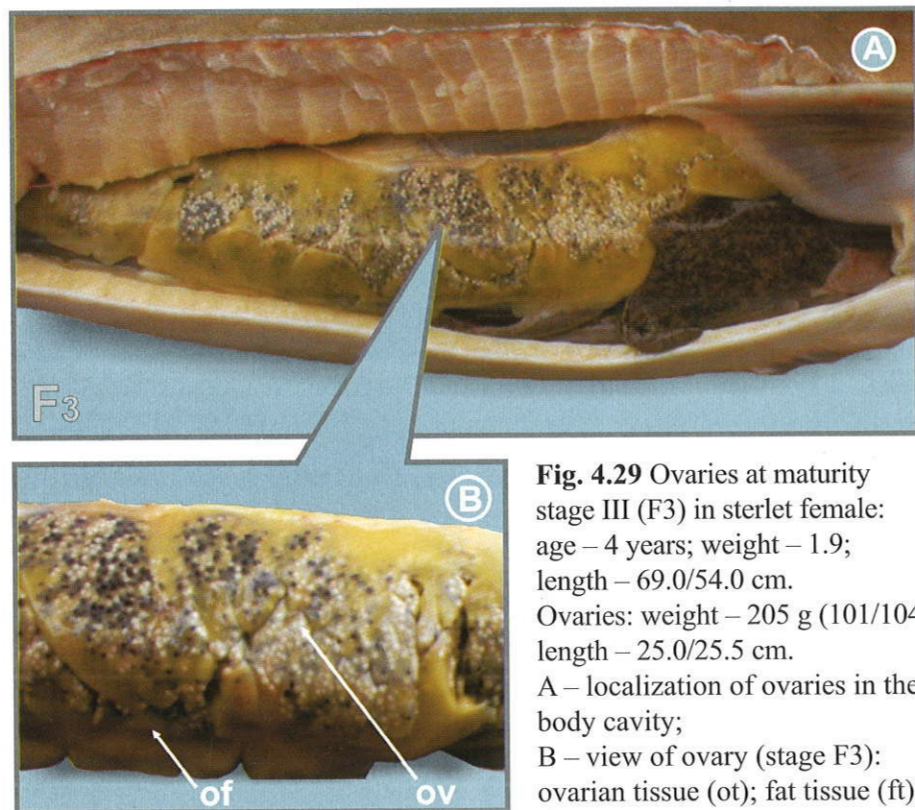


Fig. 4.28 Frontal sections of ovaries at maturity stage II-III (F2-3) (My Sono-201).

4.3.6 Female maturity stage III (F3)

Transition of the ovaries to maturity stage III (Fig. 4.29) is characterized by growth of follicles, thickening of the ovigerous lamellae and increase in linear sizes and volume of gonads. The fat content in the ovary during the stage development shows considerable decrease.

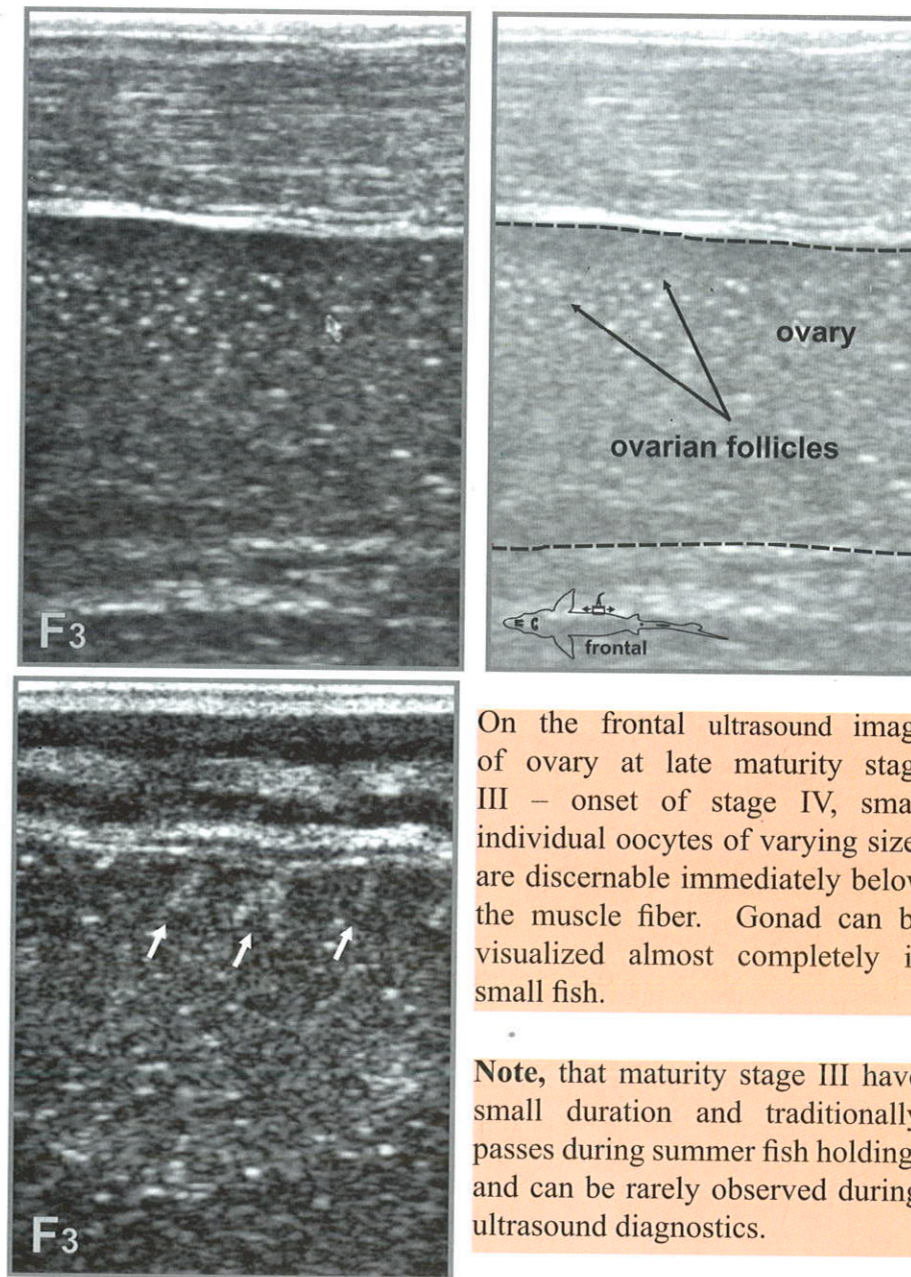
The size of white oocytes increases from 0.5-0.7 mm (at the beginning) to 1.6 – 2.0 mm. Oocytes of greyish coloration can be encountered. The nuclear polarization of pigmented oocytes is not well evinced. At the end of the stage, completely pigmented (grey) oocytes prevail among oocytes of senior generation. This is an important visual sign of maturity stage III.



On the ultrasound image, ovaries at stage III appear as a clear granular texture (Fig. 4.30). Ovigerous lamellae are evident on ultrasound image as light diffuse regions, embedded into the hypoechoic ovarian tissue, where small oocytes are visible.

In the sequel, small regions of ovigerous lamellae can be evident only in the lateral part of the ovary. The continuing growth of follicles is associated

with the decrease in the echogenicity of ovarian tissue. Gonad enlargement and yolk deposition in oocytes lead to absorption of echosignal in ovary, thus organs below could hardly be identified on echograms.



On the frontal ultrasound image of ovary at late maturity stage III – onset of stage IV, small individual oocytes of varying sizes are discernible immediately below the muscle fiber. Gonad can be visualized almost completely in small fish.

Note, that maturity stage III have small duration and traditionally passes during summer fish holding, and can be rarely observed during ultrasound diagnostics.

Fig. 4.30 Frontal ultrasound images of ovary at the end of maturity stage III and onset of stage IV (F3-4).

4.3.7 Female maturity stage IV incomplete (F4i)

At female maturity stage IV incomplete all the oocytes of the dark-gray colour close to definitive sizes (≥ 2.0 mm in case of Russian sturgeon). The polarization of nucleous oocytes on the histological sections is clearly manifested. The small remnants of fat cover (Fig. 4.31), surrounding the ovarian tissue are retained (primarily on the medial side).

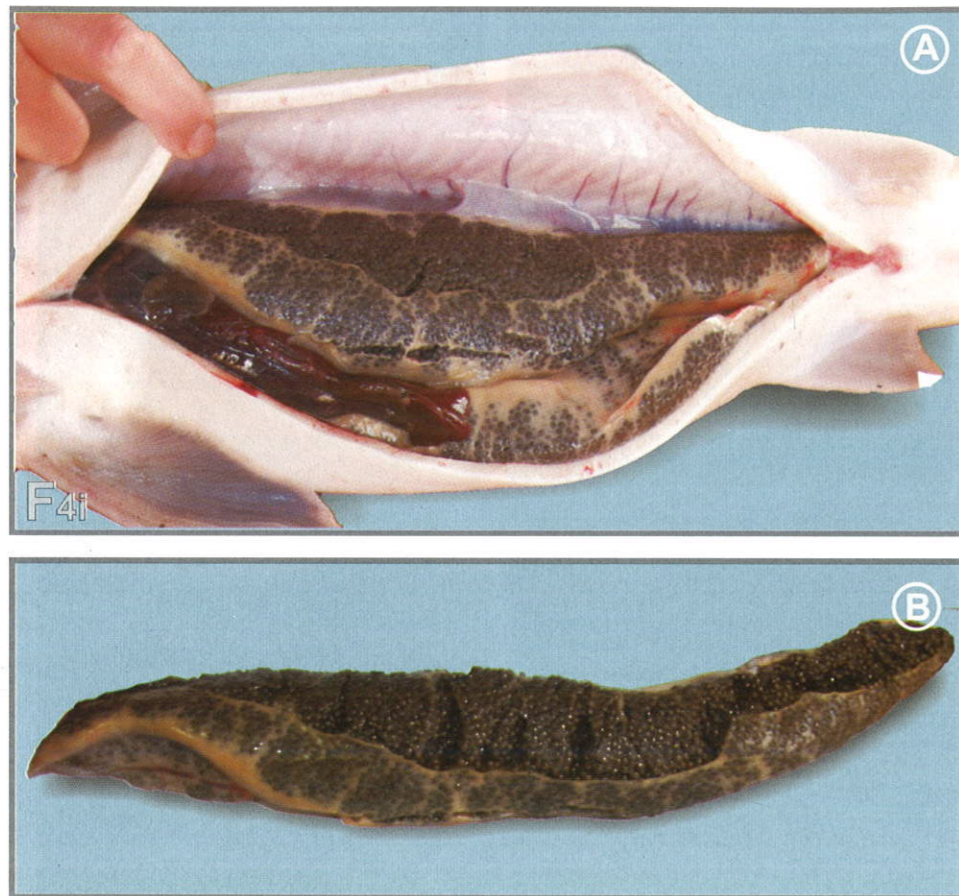


Fig. 4.31 Ovaries at maturity stage IV incomplete (F4i) in sterlet female: A – localization of ovaries in the body cavity; B – view of ovary (stage F4i).

Single large oocyte of equal size are well discernable on the images (Fig. 4.32). The ability of the ovaries to let through ultrasound waves is considerably reduced and medial side of the gonad and organs located below could not be visual.

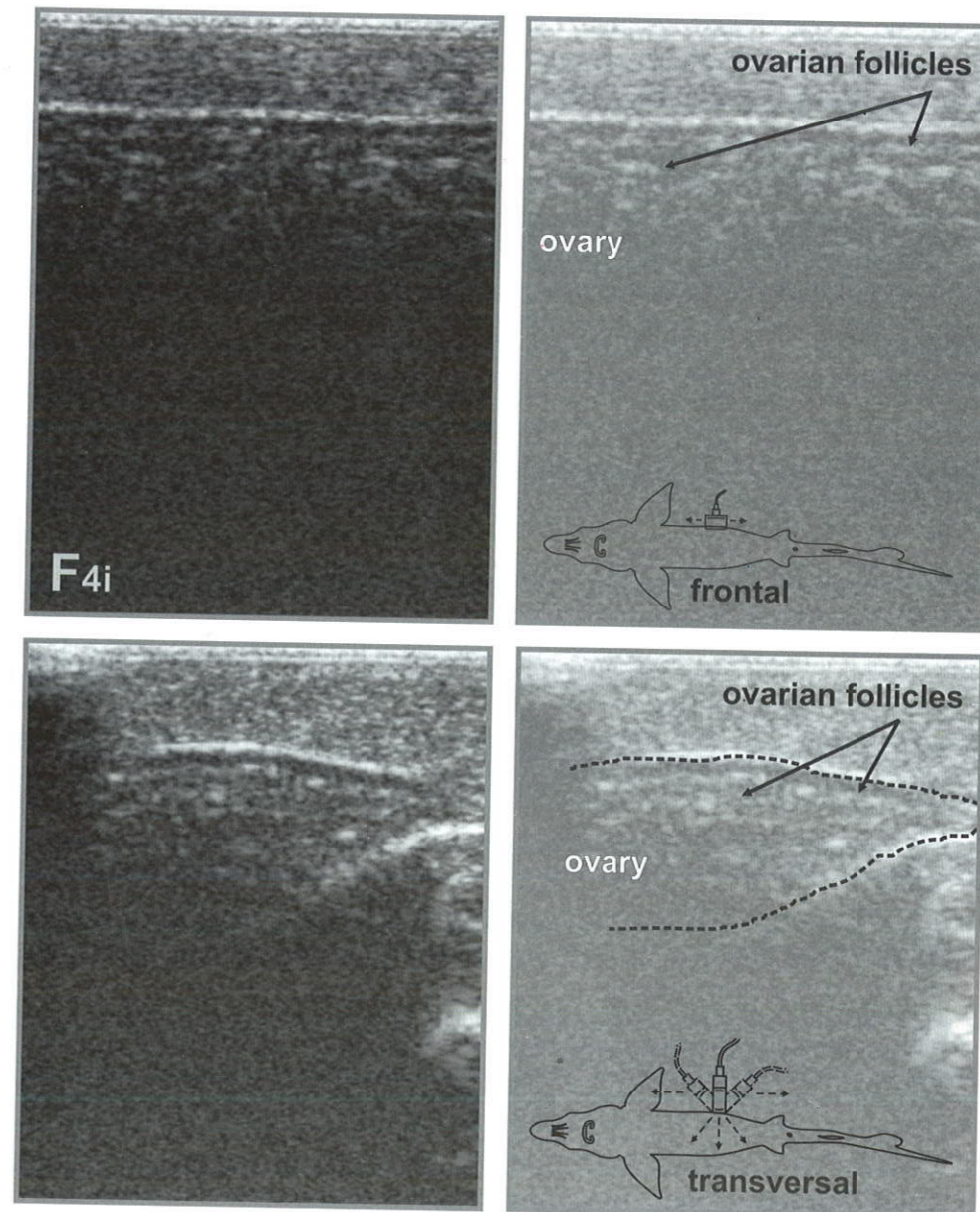


Fig. 4.32 Frontal and transverse ultrasound images of ovary at the incomplete maturity stage IV (F4i).

4.3.8 Female maturity stage IV complete (F4c)

Maturity stage IV complete (F4c) is responsive state gonadal development. The lack of fat is evident (Fig. 4.33), while the ovaries fill almost the entire body cavity, and completely pigmented oocytes (black in colour) reach the definitive size (diameter >2.9 mm, weight >16.7 mg in case of Russian sturgeon). The oocyte nucleus is off-center towards the animal pole and located in the fine-grained region of the yolk (Dettlaff et al, 1993).

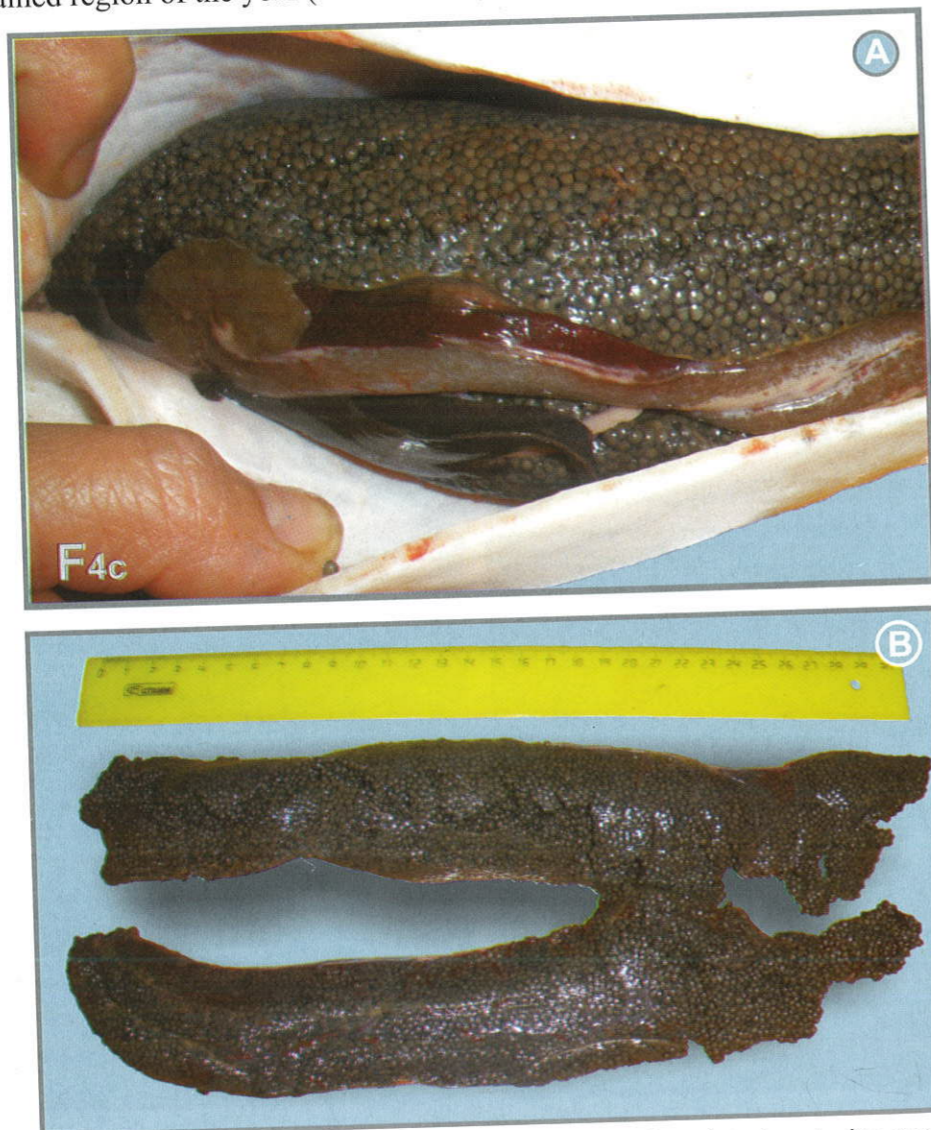

Fig. 4.33 Localization of gonad in the body cavity of sterlet at maturity stage IV complete (F4c): A – localization of ovaries in the body cavity; B – view of ovary.

On the image (Fig. 4.34) single oocytes are evident as granular inclusions of almost equal size, the ovary shows granular heterogeneous appearance (Chebanov et al., 2004, Chebanov, 2005). Lines of oocyte get more apparent.

At this, ultrasound is almost completely absorbed in the upper (1 cm) layer of the ovary and hence the medial part of the gonad and organs below are not discernable.

Thus, the key differences between echograms of ovarian maturity stages IV complete and IV incomplete are as follows:

- more evident lines of oocytes of equal size;
- the higher absorption of echosignal by upper layer of mature oocytes;
- absence of visualization of the medial part of ovary.

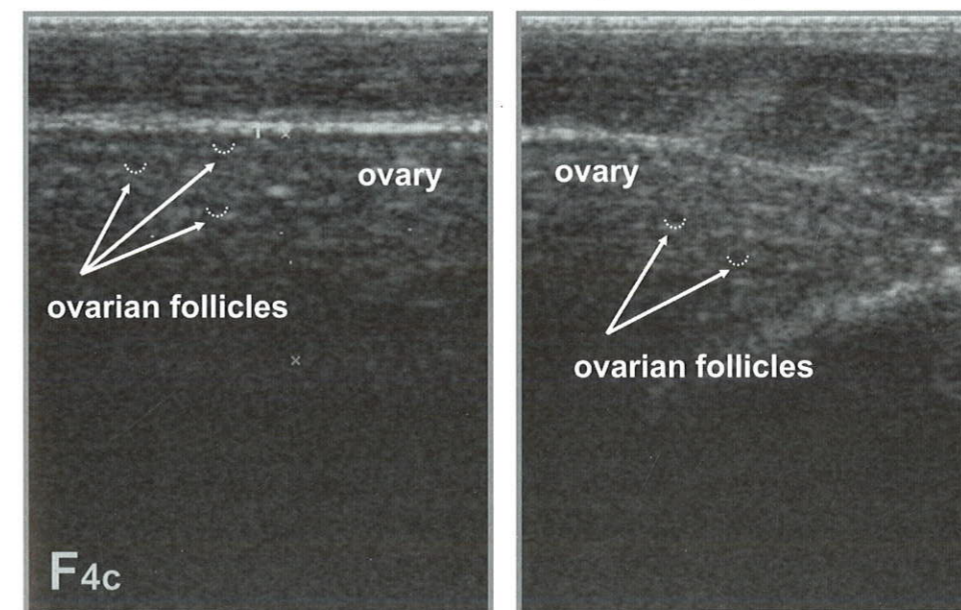
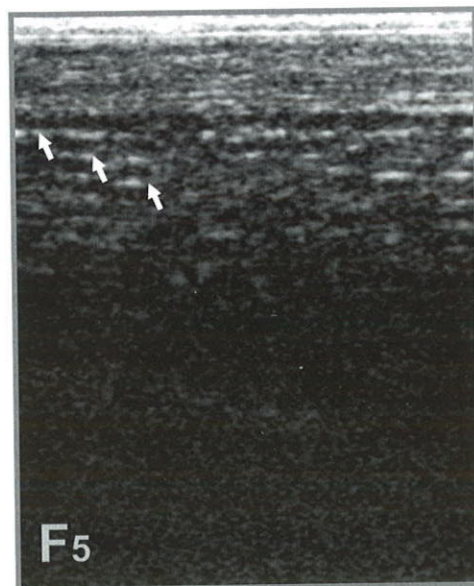

Fig. 4.34 Frontal and transverse ultrasound images of ovary at maturity stage IV complete (F4c).

4.3.9 Female maturity stage V (F5)

Female maturity stage of ovary development V is associated with spawning (egg ovulation). On the image (Fig. 4.35) the ovulated eggs of the equal size, arranged in the rows are well defined. It is a primary visual distinction of echograms at the frontal scanning of the ovaries at stage of maturity V from stage IV complete. Under the rows of eggs, effect of distal acoustic enhancement is registered, manifested as white (hyperechoic) dashes on the screen.



Note, that mentioned above differences between ovary development stage IV complete (F4c) and stage V (F5) allows accurate timing of complete eggs ovulation, that is very important for hatchery practice. To avoid affect of stressors, in order to evaluate rate (degree) of ovulation in large sturgeons (beluga etc) it is recommended to use ultrasound technique, while fish being held in water.

Fig. 4.35 Ultrasound image of ovary at maturity stage V (F5).

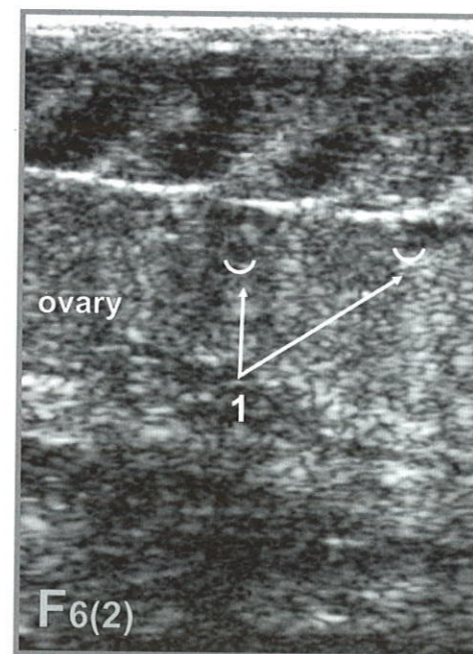
4.3.10 Female maturity stage VI (F6)

After the natural spawning or artificial non-lethal eggs extraction from ripe femails, resorbing mature oocytes and oocytes of junior generation remained in the ovary. Ovaries of post spawn fish transit to maturity stage II.

Typical images of the ovaries at maturity stage IV are presented in Bruch et al. (2001), who reported that after the spawning “ovaries immediately after spawning are folded, the ovarian tissue appears less organized, and the most samples a mushy, punkish and flaccid appearance, and with little to no associated fat.”

The ultrasound images of the ovaries at maturity stage VI (Fig. 4.36) are similar with those of the ovaries at stage II, while the residual resorbing mature oocytes is the prime difference between these echohrams. The ovarian tissue of the gonad is of moderate echogenicity. Immediately after the spawning/extraction by method microsurgery of oviduct (Podushka, 1999), oocytes of junior generation are not well evident due to their small sizes (0.2 – 0.4 mm).

Six month post spawn, the single resorbed oocytes (hypoechoic inclusions of irregular shape) can be visual on the echogram. Small oocytes of different size from new generation are well evident.



Note, that ultrasound images of post spawn sturgeons are slightly different from those of first spawning fish. This is related to fat deposition in the ovary) and sclerotization of hematomas and break in the ovarian tissue, which is represented by a region of mixed echogenicity. In addition, the ovaries in post spawn sturgeons have considerably larger size than that of firstly mature ones. This is well evident on the vertical measuring scale at the left side of the echogram (Fig. 4.36).

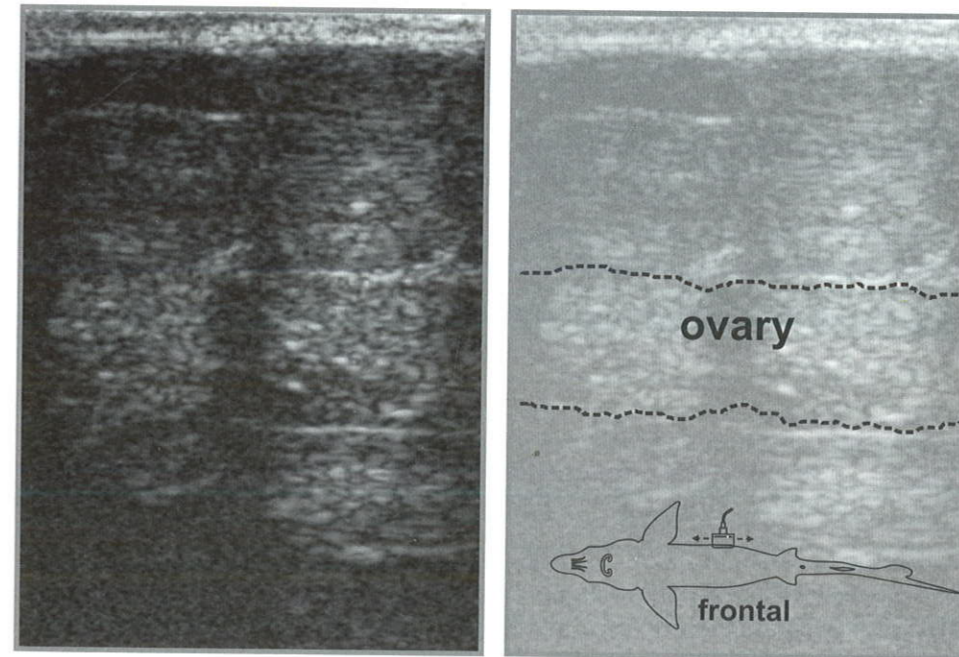


Fig. 4.36 Frontal ultrasound image of ovaries 10 months post extraction of ovulated eggs (1 – resorbing mature oocytes).

4.4 Ultrasound images of mature testes and eggs resorption

4.4.1 Males

During summer season at hatcheries/farms of industrial type, as well as at long-term holding, overripe males and resorption of the testes can be observed, being expressed by strong hyperemia and “loosening” of the testes.

On the image this process is expressed by reduction in testis echogenicity (Chebanov et al., 1999, 2004). At this, at the onset of this stage (Fig. 4.38), tunics and margins of the testis are well-defined, while during the further overlapping they became less clear.

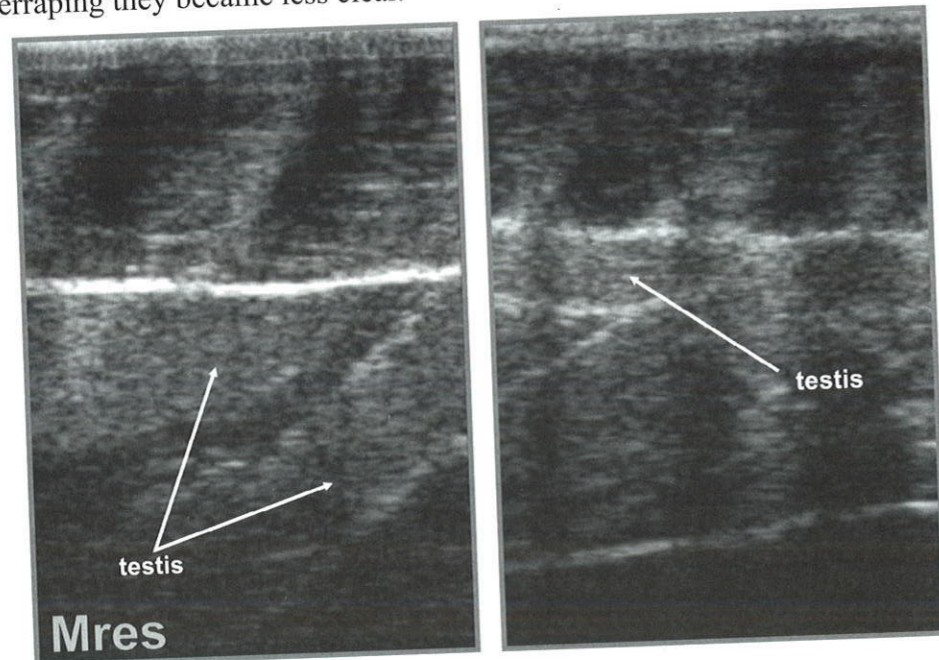


Fig. 4.37 Ultrasound images of resorbed testes in post spawn male (early resorption).

4.4.2 Females

In case of spawning failure, for example at exposure of mature females (F4c) more than 20 days to spawning temperature, resorption (atresia) of mature (ripe) oocytes and follicular epithelia occurred in the ovaries or the body cavity (Goncharov et al, 2009). On the ultrasound image (Fig. 4.38 & 4.39) this process is expressed in the following way: residual mature oocytes get irregular shape and lose distinct margins (A), oocytes of junior generation (B) are evident between resorbing eggs (oocytes). The echogenicity of the ovary is elevated in the course of resorption development.

In some cases, after ovulated eggs extraction for reproduction (caviar production) or after natural spawning, gonads (F6) exhibit considerable decrease in size, get inflamed and lose previous echogenic structure. Sex of such fish can hardly be identified on the echogram.

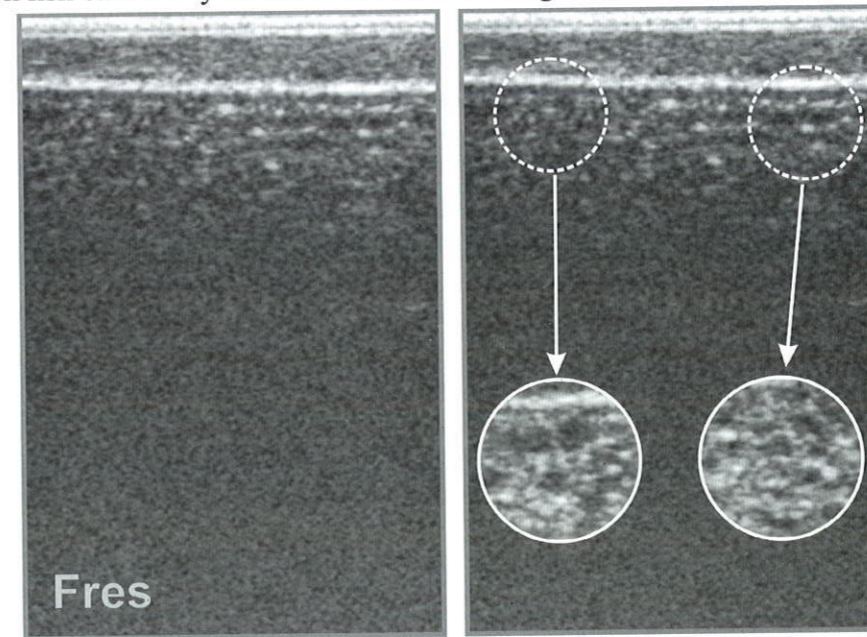
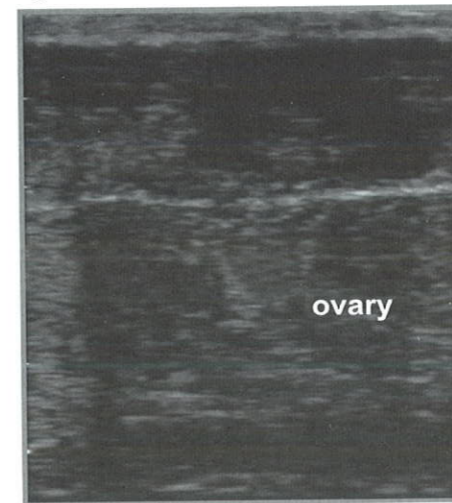


Fig. 4.38 Ultrasound image of female at stage VI (Fr) with eggs in process of early resorption.



Note, that timely ultrasound diagnostics of the onset of partial oocyte resorption allows to avoid full resorption of ripe ovarian follicles by control of thermal regime or immediate usage of mature females for artificial reproduction. In some cases, when the process of resorption has being transferred to the considerable part of ovary, ultrasound diagnostics allows to avoid inefficient use of such females in the spawning campaign.

Fig. 4.39 Frontal ultrasound image of ovary in Russian sturgeon female at maturity stage VI (F6) four months post eggs extraction.

4.5 Non-invasive ultrasound monitoring of gonadogenesis of large sturgeon specimens*

The benefits of ultrasound diagnostics for optimization of broodstock of rare and endangered species (*ex situ* and *in situ*) are evident. This is especially urgent in case of such species as *A. sinensis* (Fig. 4.40), *A. sturio*, studying and holding of which require application of non-traumatic techniques (others than biopsy, laparoscopy, endoscopy and alike ones).



Fig. 4.40 Anaesthesia of large Chinese sturgeon specimens using MS-222 sedative.

Really, such characteristic of Chinese sturgeon as ability to accumulate the trophoplastic deposition is associated with long-term spawning migration (Wei et al., 1997, Chang, 1999, Xiao et al., 2005). Despite the necessity of considerable energy deposit in order to pass more than 3300 km up the stream (including warm summer period of the second year of migration that would be possible only in a very deep river considering the climate conditions of South China), Chinese sturgeon in the Yangtze River was not feeding. Undoubtedly, this required considerable trophoplastic deposition during the period of fattening in the sea and estuary of the Yangtze River.

* Authors are much grateful to Prof. Jianbo Chang, Dr. Zhu Bin (Institute of Hydroecology), and Prof. Xiao Hui (Chinese Sturgeon Research Institute) for organization of ultrasound non-invasive examination of large specimens Chinese sturgeon from the domestic sturgeon broodstock.

Due to considerable fat deposition, as reported in Fan et al., (2006), even fish laparoscopy does not allow reliable early (under 5 years of age) sexing and maturity staging of Chinese sturgeon ranged from 18 to 25 kg. Despite the fact that females could reach maturity stage II at 3 years (weight range – 4-8 kg); the biopsy can hardly be applied due to low width of testes (1.5-2.5 mm), ranged from 350 to 1000 μm on the section.

Due to large sizes of examined *A. sinensis* specimens, the use of conventional linear transducer (frequencies range 5-7.5-10 Mhz) at ultrasound scanning (Chapter 1, Fig. 1.1) was less effective because of its high frequency associated small depth of scanning (penetration), despite the high resolution of the resulting images (Chebanov, 2005).

Hence, the main type of transducer to be used while performing scanning of large specimens is convex one (Fig. 4.41) with frequencies 2-3.5 Mhz, with depth of ultrasound penetration above 20 cm. Unfortunately, this transducer has comparatively low resolving capacity (Chebanov and Galich, 2008).

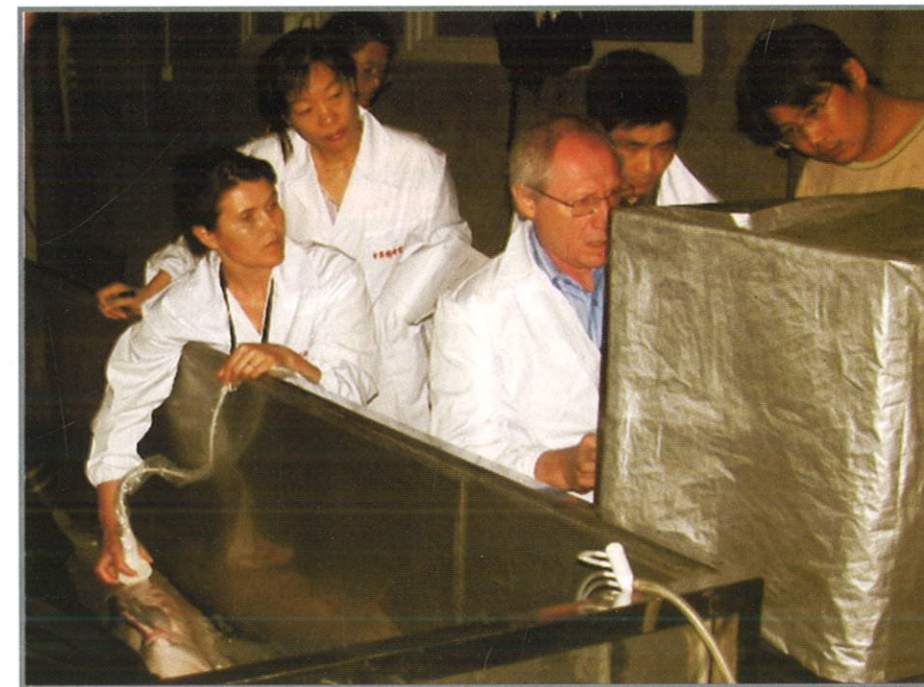

Fig. 4.41 Non-invasive ultrasound stress-free examination of sex and stage of large specimen of Chinese sturgeon (transverse scanning is conducted while fish being kept in water).

The sex and maturity stage identification procedure typically takes up to 5-10 seconds. Anyway, in some cases (for instance at high air or water temperature) administration of anaesthetics should be conducted for larger specimens (above 80 kg) in the tank (with depth of 40-50 cm). Tricaine methane sulfonate (MS-222) (Mohler, 2003) or clove oil (eugenol) (Podushka, Chebanov, 2007) are used anaesthetics.

Ultrasound examinations were conducted in the mode of frontal and transverse (Fig. 4.42 & 4.43) B-scanning.

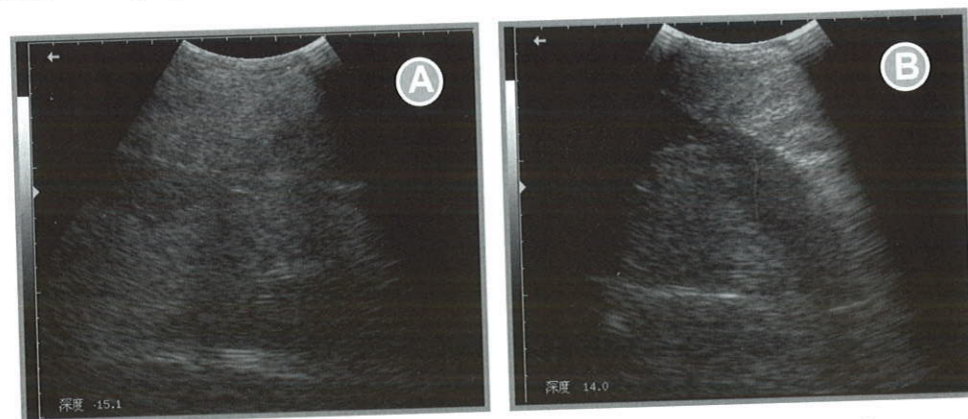


Fig. 4.42 Ultrasound images ovary of Chinese sturgeon female at maturity stage II fatty (F2f) (length (L/l) – 233/200 cm): A – frontal section; B – transverse section.

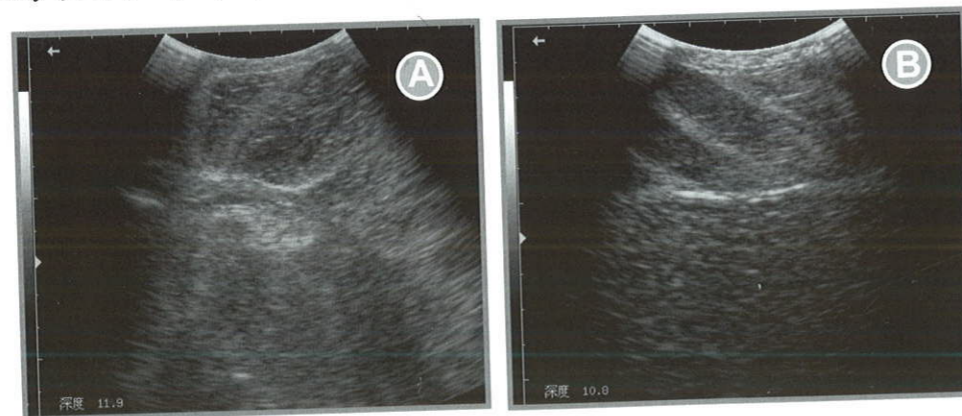


Fig. 4.43 Ultrasound images ovary of Chinese sturgeon:
A – transverse ultrasound image of Chinese sturgeon female at maturity stage II fatty (F2f) (body length (L/l) – 212/195 cm, weight – 85 kg);
B – Frontal ultrasound image of Chinese sturgeon female at maturity stage IV incomplete (F4i).

During the examination all the basic scanning settings, excluding focus, depth of penetration and frequency of ultrasound penetration were constant.

Ultrasound images of Chinese sturgeon females and males with indication of fish sizes and depth of scanning from the fish body surface (cm) are presented on the figures. Differences between the various stages of maturity of males and females meet the described above diagnostic markers (paragraph 4.2 & 4.3). During the examination, it has been revealed that reliable ultrasound sexing of Chinese sturgeon is also can be performed at maturity stage II (in case of females at late stage II of gonad maturity).

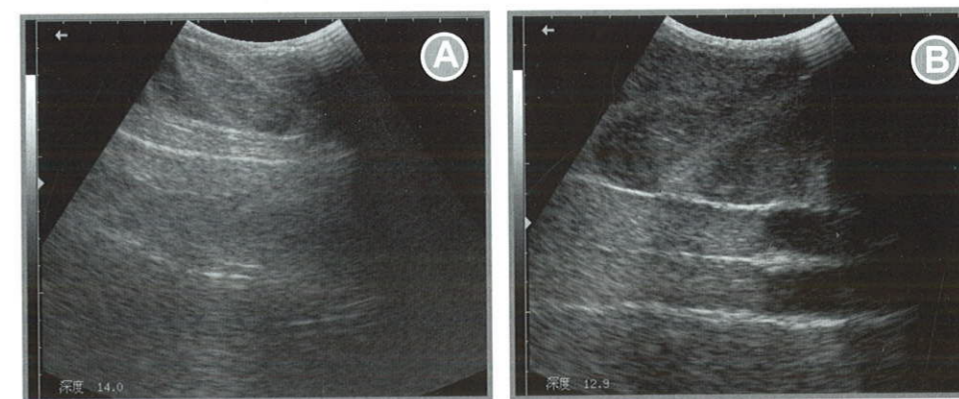


Fig. 4.44 Frontal ultrasound images of Chinese sturgeon males:
A – testis maturity stage II (M2) (length (L/l) – 180/155 cm);
B – testes maturity stage III (M3) (length (L/l) – 180/162 cm).

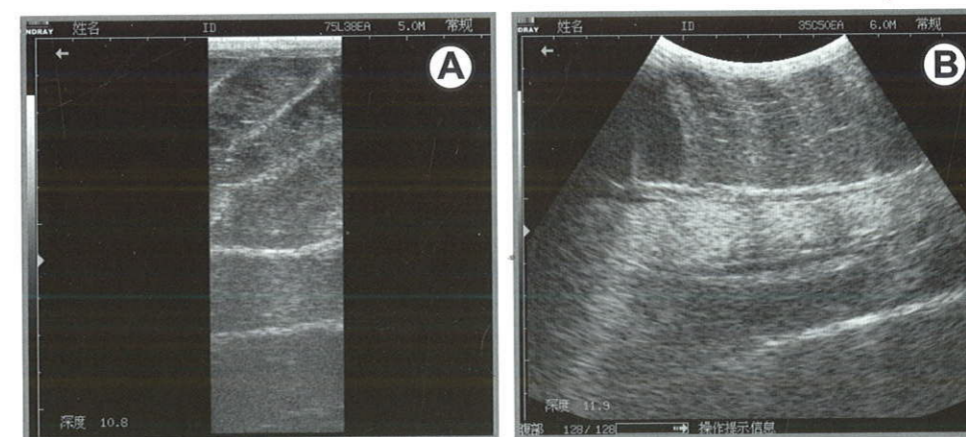


Fig. 4.45 Frontal ultrasound images of Chinese sturgeon males:
A – linear transducer;
B – convex transducer.

Note, that constant monitoring of gonadogenesis of sturgeons in domestic broodstock allows, as it has been mentioned above, to prevent resorption of mature oocytes by timely regulation of thermal regime, water current velocity and feed deprivation. In addition, application of ultrasound diagnostics enables to avoid stress with fish being kept in water while performing a number of non-invasive examinations.

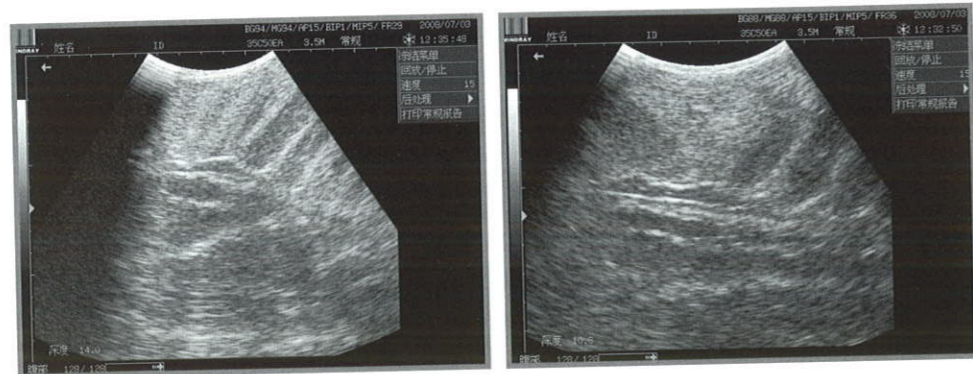


Fig. 4.46 Some frontal ultrasound images of Chinese sturgeon males:



Fig. 4.47 Large Chinese sturgeon specimens.

Chapter 5 Functional Ultrasound Non-invasive Diagnostics of Inner Organs in Sturgeons

5.1 Ultrasound images of internal organs in sturgeons

For a long time, ultrasound diagnostics has been effectively used in Veterinary (Goddart, 1995) in the course of studying functional malformations and morphological anomalies of inner organs of agricultural and domestic animals.

The gained experimental background of the present book author's has proven that application of inexpensive ultrasound systems for sturgeon diagnostics is also possible.

Vaihi et al. showed (2001) the possibility of 5-7.5 Mhz transducers application (Chapter 2) for study 5 large wild individuals of Persian sturgeon (average size 152 cm, weight 25.5 kg and age 16.5 year old) and best ultrasonographic sections for different organs of the digestive system of sturgeon have been suggested (Table 5.1).

Table 5.1 Best ultrasonographic windows for different organs of the digestive system of sturgeon (Vajhi et al. 2001)

Approach Organ	Tr.		Tr. ventral	Fro.		Sag. ventral	Para-sagittal ventral		Obl. pec. fin	
	L	R		L	R		L	R	L	R
Mouth			*			*	*	*		
Esophagus			*			*				
U-stom.	*		*	*						
Muscular stomach	*	*	*	*	*	*	*	*		
Opening between U-stom. & muscular stom.										*
Pylorus		*	*		*					*
Descend. Small intestine	*	*	*	*	*	*				*
Ascend. Small intestine	*	*	*	*	*	*				
Spiral colon	*	*	*	*	*	*				
Rectum	*	*	*	*	*	*				
Pyloric appendage	*		*	*			*			
Right & middle lobes of liver		*	*		*	*			*	*
Left & middle lobes of liver	*		*	*		*	*			*
Gall bladder								*		*

Tr: transverse, Fro: frontal, Sag: sagittal, Obl: oblique, Pec: pectoral, Stom: stomach, Desend: descending, Ascend: ascending; L: left; R: right.

The non-invasive examination of inner organs of sturgeon domestic broodstocks is urgent, especially of reared and endangered. The peculiarities of ultrasound examination of state of different inner organs (pathological echoanatomy), as well as diagnostic markers of typical developmental anomalies of the reproductive system, diseases and traumas of internal organs of sturgeons are described in this chapter.

5.1.1 Cartilaginous tunic of notochord

The cartilaginous tunic of notochord is the transversal scanning shows it to have a roundish compound echogenous structure, the external tunic is cartilaginous, hyperechogenous, the internal contents (notochord) is echoheterogenous (Fig. 5.1).

5.1.2 Kidneys

Kidneys (*ren*) appears on the frontal section as an almond-shaped structures of mixed echogenicity. They are located between the abdominal cavity and (from which they are separated by echoic membrane) and notochord and have fine grained structure of the echogenicity similar to that of the gonads along the intermediate and the spiral guts on the spinal area (Fig. 5.1). They are transpierced by blood vessels and covered by the membrane.

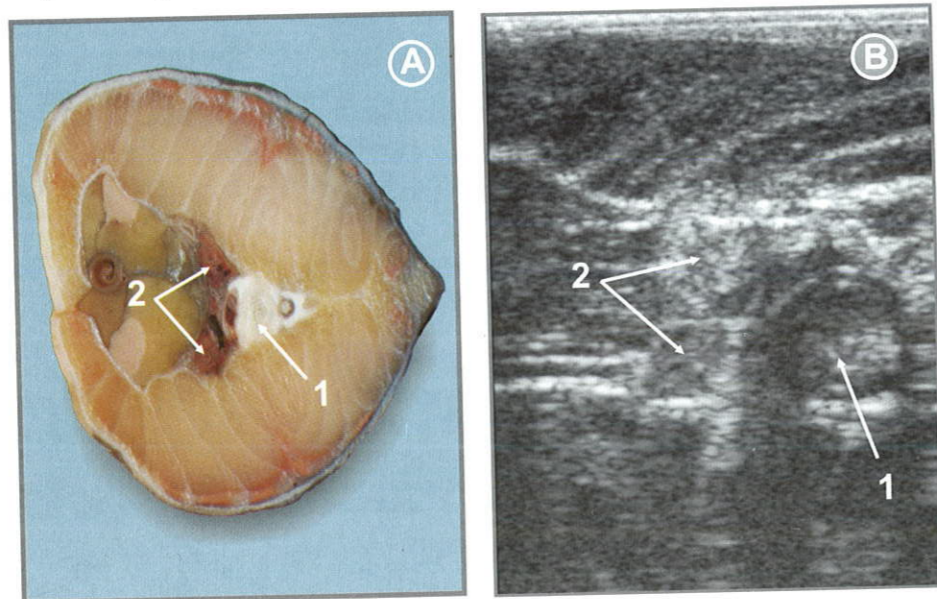


Fig. 5.1 View of the Russian sturgeon male, kidney region (1 – notochord, 2 – kidneys): A – view of transverse section (cross-anatomy); B – transverse ultrasound image.

5.1.3 Liver

It is difficult to diagnose both lobes of liver simultaneously, and in full volume due to some anatomic peculiarities of sturgeons. The fish is placed into a specially prepared bath (Table 5.1) on its back; the area of scanning is directly under the pectoral fins at the angle of 30° in the dorsal-ventral direction. On the ultrasound image, the liver parenchyma appears as fine-grained structure, characterized by a good penetration of echosignal (hyperechoic), as well as by image areas of increased echogenicity (fibrous tissue), differing from the remained parenchyma. The edges of liver are even; on the right lobe of liver the gallbladder is well visualized.

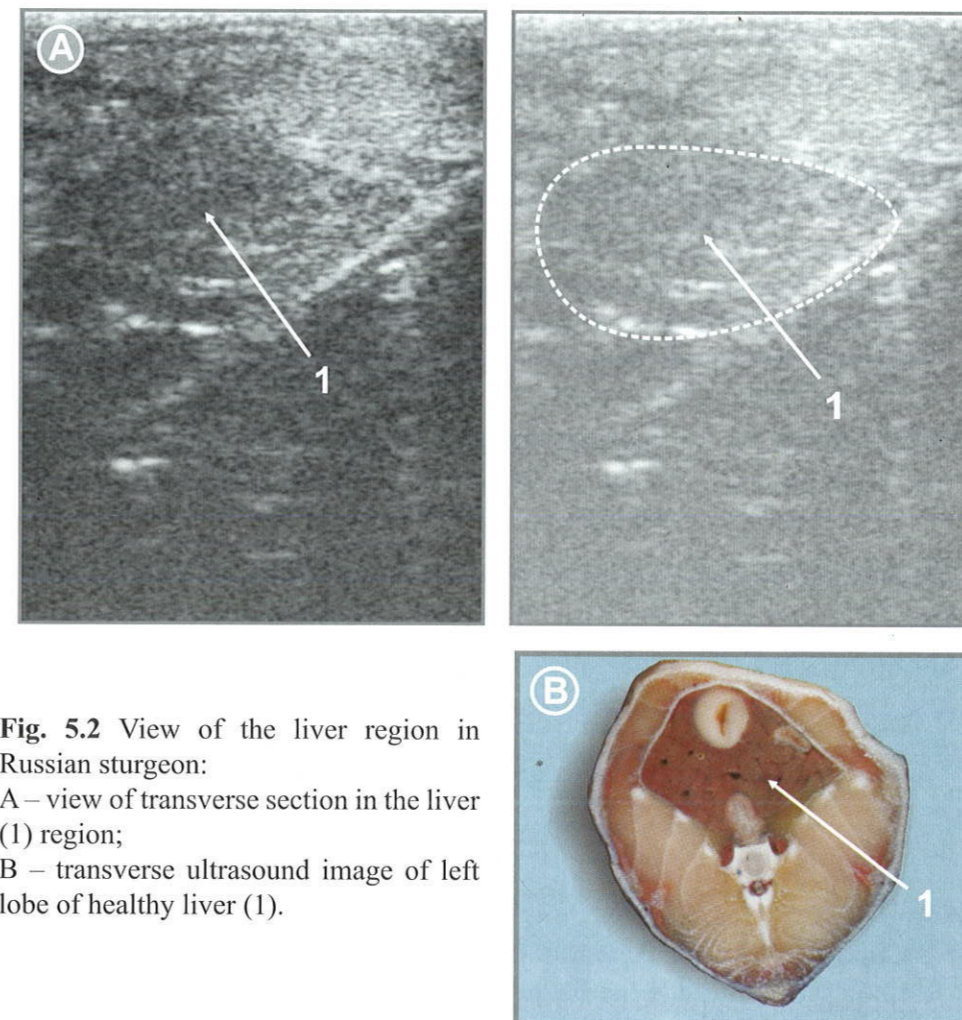


Fig. 5.2 View of the liver region in Russian sturgeon:
A – view of transverse section in the liver (1) region;
B – transverse ultrasound image of left lobe of healthy liver (1).
C – transverse section of the liver (1) region.

5.1.4 Gall bladder

The gall bladder is located directly under the muscle fiber and «immersed» in the liver parenchyma, and have a irregular roundish form, and the mucosa of the gall bladder on ultrasound image are expressed not clearly. The anechogenous clearance looks on the screen like a roundish dark spot with acoustic enhancement under it.

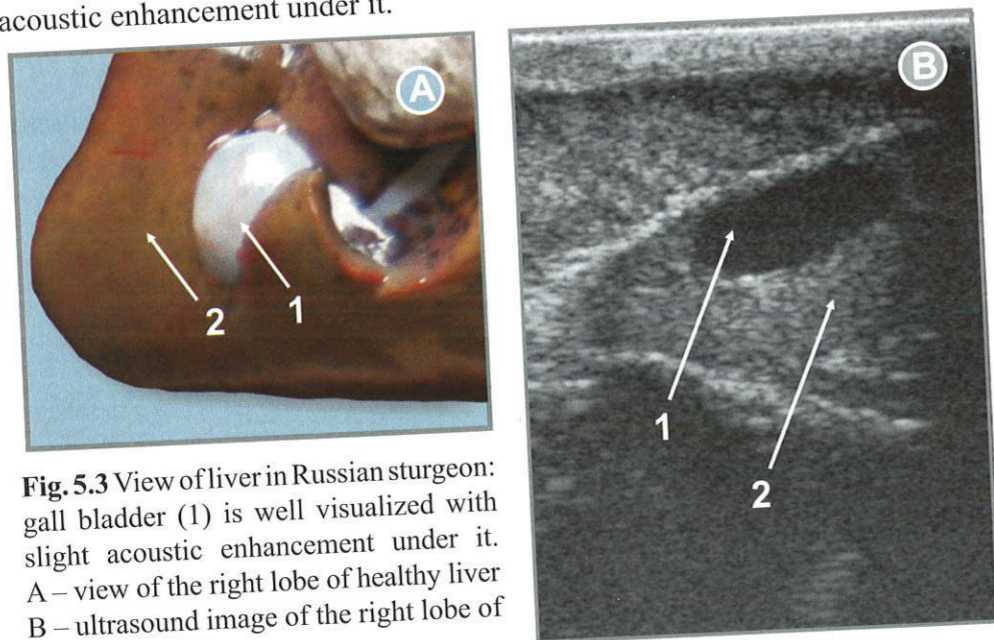


Fig. 5.3 View of liver in Russian sturgeon: gall bladder (1) is well visualized with slight acoustic enhancement under it. A – view of the right lobe of healthy liver B – ultrasound image of the right lobe of healthy liver (2).

To increase the efficiency of express ultrasound diagnostics of domesticated replacement sturgeon broodstocks health it is necessary to develop a point scale of liver pathology based on the well defined differences between ultrasound images of healthy and pathological liver in sturgeon. At this, character of liver margins, obesity (lipoid, cirrhotic degeneration) and changes in parenchyma structure may be used as diagnostics criteria of liver degradation level (as it has been shown above).

The typification of ultrasound images of the gall-bladder at different pathology degree can be performed in the similar way.

5.1.5 Heart

The site of heart ultrasound examination is located in the upper area between the pectoral fins. At frontal positioning of the transducer, acoustic contact gel should be used to provide the better interface with a limited surface. On the screen the ventricle looks like a rounded anechoic region. The external tunic

of ventricle appears as an area of mixed echogenicity, covered with a lymphoid gland of bubble-like structure (typical for sturgeons). Usually, the internal hyperechoic boundary of the ventricle with anechoic area is well discernable beneath the gland. The atrium and venous sinus, that looks like a hollow tube with clear hyperechoic boundaries, and internal anechoic (dark – almost black) layer are located in the depth under the ventricle (Fig. 5.5).

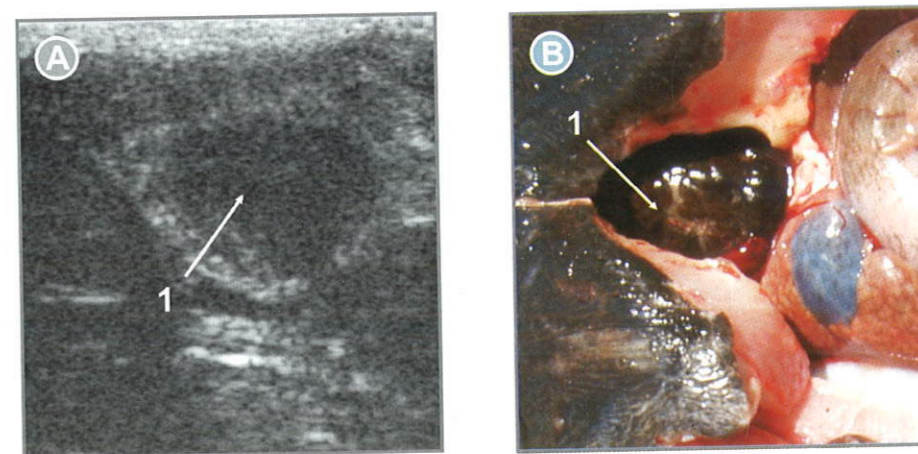


Fig. 5.4 View of heart in Russian sturgeon: A – transverse ultrasound image of heart (1); B – dissected view of heart (1).

5.1.6 Blood vessels

The blood vessels appears on the ultrasound images as a prolonged cavity (at frontal section) or rounded structure (at transverse scanning) with hyperechoic (almost white) walls and an anechoic (almost black) inner gap.

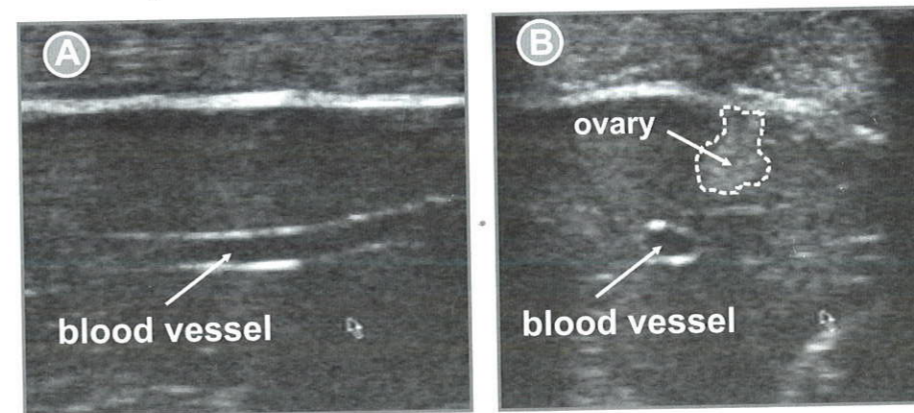


Fig. 5.5 Ultrasound images of blood vessels in Russian sturgeon: A – frontal ultrasound image of a blood vessel; B – transverse ultrasound image of a blood vessel and ovary.

5.1.7 Pyloric gland

The pyloric gland is visualized at transvers ventral scanning just under the left lobe of the liver. It has clear hyperechoic boundaries and complex internal lobular structure. On the screen of monitor it is seen as the dark anechogenous sections, separated by the hyperechoic lines (Fig. 5.6).

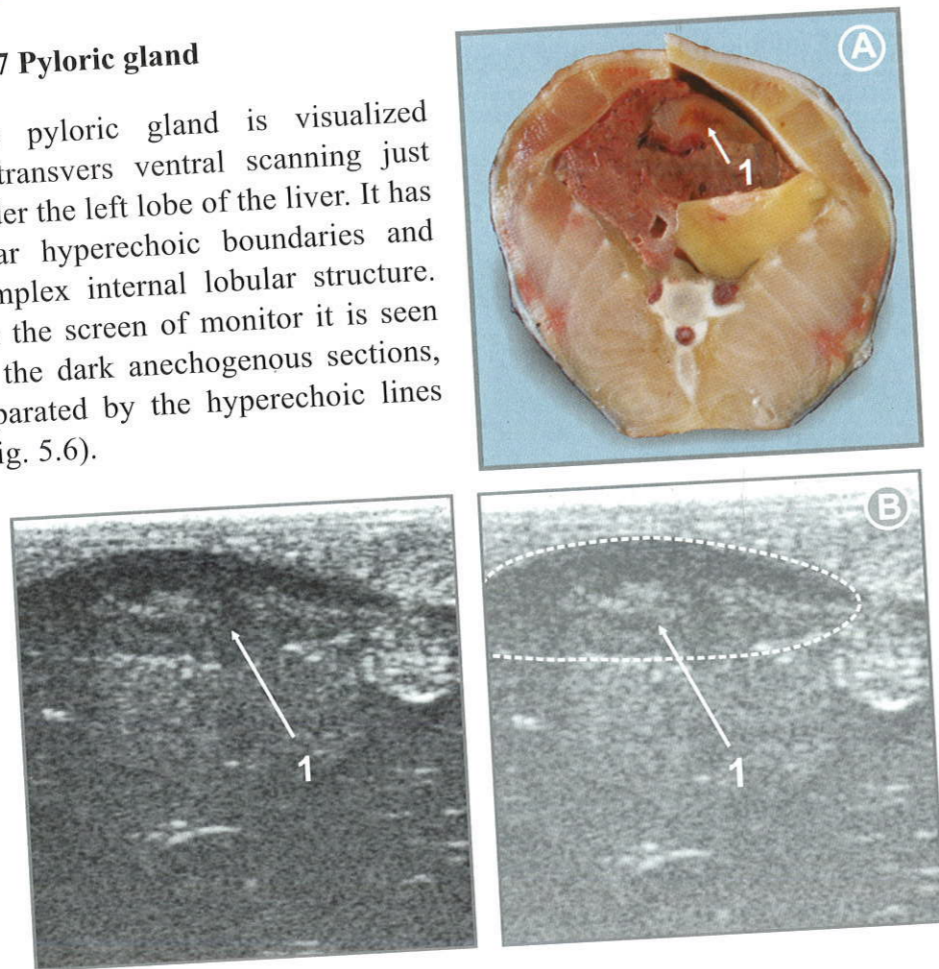


Fig. 5.6 View of the pyloric gland area in Russian sturgeon:
A – dissected view of the pyloric gland area (1);
B – ultrasound image with visualization of the pyloric gland (1).

5.2 Ultrasound non-invasive diagnostics of developmental anomalies in the reproductive system of sturgeon (pathologic echoanatomy)

Application of non-invasive express method allows to cull sturgeon individuals with abnormalities of the reproduction system, those are not promising for hatchery propagation. Moreover, various malformations identification on the ultrasound images, enable monitoring of sturgeon reproductive system development, in similar way it is conducted in natural water bodies at

bioecological indication of habitats degradation in the wild, as well as at assessment of breeders holding conditions (thermal regime, water quality, diet formulation etc.) in aquaculture or at selection effect evaluation in programmes of sturgeon and domesticated forms pedigree breeding (Chebanov, 2005b).

Hence, the development of functional diagnostics methods allows to enhance the efficiency of sturgeon health evaluation, especially in the domestic broodstocks of rare and endangered sturgeon species, when the prolonged feeding by of pellet feeds (for example, with high level of fat) can lead to serious damages (degeneration) of the liver and other organs. The express technique application will be especially useful for wild breeders and immature sturgeon preselection intended for predomestication (Bilio, 2007) (adaptation to artificial holding conditions). In fact, efficiency of pre-culling of individuals with “hidden” pathology of inner organs using ultrasound diagnostics can be hardly overestimated due to labour intensiveness and high cost of long-term domestication of “wild” fish.

5.2.1 Lobularity of testes

Lobularity of testes (Fig. 5.7) is the division of testicular tissue into lobes, small from the norms point of view. At this, hypoechoic (dark strips) are evident on the ultrasound image at frontal scanning.

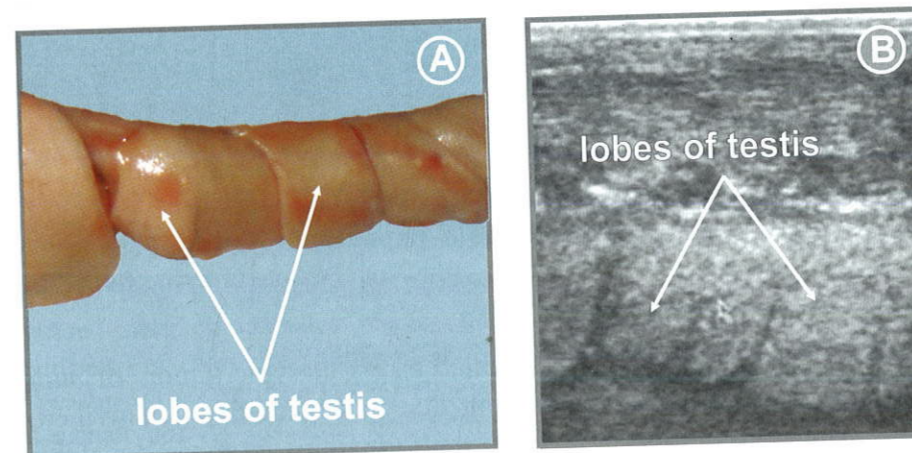


Fig. 5.7 View of lobes of testis in Russian sturgeon:
A – view of lobes of testis;
B – frontal ultrasound image of lobes of testis.

5.2.2 Cyst

Cyst (from greek *kystis*) is a pathological structure with tight walls and entirely filled with liquid. The cysts (2-4 mm in diameter) occurred in the testicular tissue of sturgeons at different maturity stages (Fig. 5.8). On the echogram they appear as thick (wall) rounded anechoic structures with acoustic enhancement below.

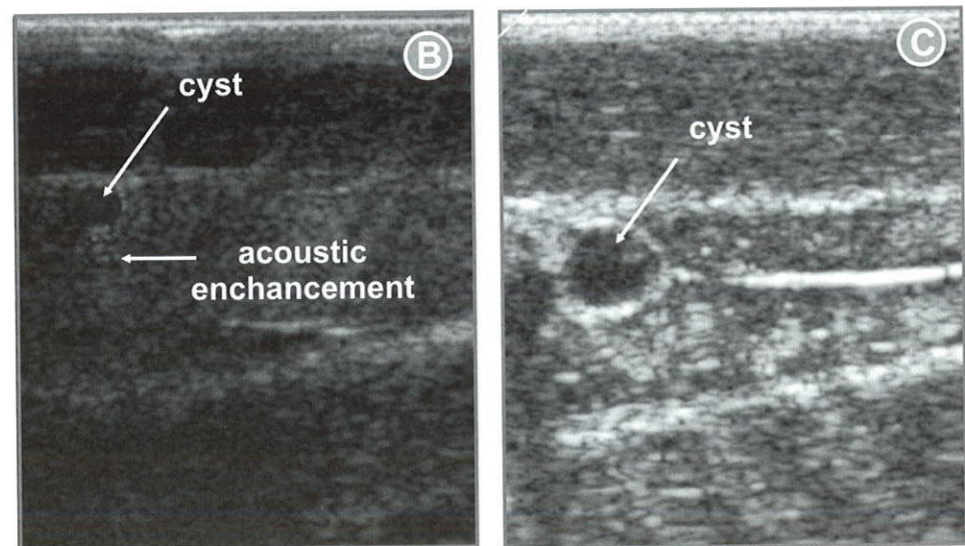


Fig. 5.8 View of cyst in the sturgeon body cavity: A – dissected view of cysts in the Russian sturgeon testis; B – ultrasound image of cyst with distal acoustic enhancement; C – ultrasound image of cystic formation in the body cavity of 2 years old sterlet female.

The cystic formations can be identified as organotypic tumors of human lipomas and fibromas type, developing due to degeneration of ovigerous lamellae (Moiseeva et al., 1997). Such malformations in gonad development affect the reproductive performance of fish, but do not hamper the normal development of gametes in the other gonad portion.

Similar neoplasms can be formed as well, at development of tumors, granulomas and parasitic invasion.

5.2.3 Sklerotization

Sklerotization (from greek *sklerosis*) is hardening of the germinal tissue regions caused by violation in blood circulation due to age changes, after many times obtaining of gametes or inflammation. It is expressed in alteration of gonad tissue by connective tissue and formation of cartilaginous neoplasms.

5.2.4 Fatty degeneration of ovaries

Fatty degeneration of ovaries is due to obesity of fish held in warm water farms at year round intensive feeding. At this, single islets of germinal (testicular) tissue with small quantity of mature oocytes are visible (Fig. 5.9).

Obligatory temporal (2 months) holding of females at low water temperatures (4-5°C), associated with feed deprivation, is recommended to avoid obesity, especially aiming at synchronization of gametogenesis majority of females (Chebanov and Billard, 2001, Chebanov et al., 1999, 2001, 2004). This is of great importance for broodstock management optimization and control of reproduction in large sturgeon fish farms and hatcheries.

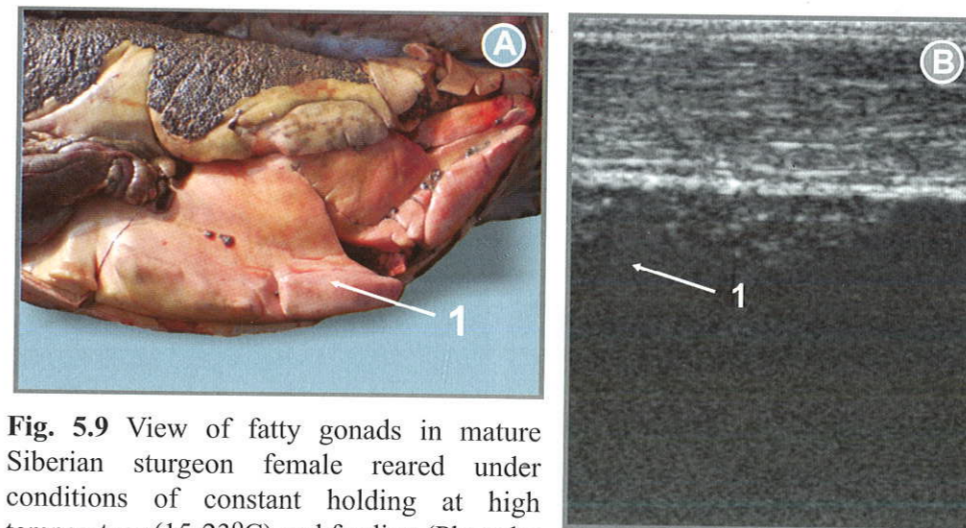


Fig. 5.9 View of fatty gonads in mature Siberian sturgeon female reared under conditions of constant holding at high temperature (15-23°C) and feeding (Photo by E. Khachatryan): A – dissected view of fatty gonad; B – frontal ultrasound image.

5.2.5 Hermaphroditism

Hermaphroditism in sturgeons is encountered when ovaries and testes are located in one gonad. Specimens with one gonad represented by a testis and second one by an ovary are rarely occurred.

As reported in (Williot, 2002, Williot et al., 2005), hermaphrodites can reach up to 5% in one generation for sterlet (>14 years). The incidence of hermaphroditism of the same frequency are reported for other sturgeon species both in aquaculture and hatchery produced breeders in natural water bodies. It should be noted that due to this reason in some cases sex determination using ultrasound technique conducted in one part of the gonad can lead to errors in separation of males from females in sturgeon fish farms.

5.3 Express diagnostics of diseases and traumas of sturgeons internal organs

Besides described above anomalies of reproductive system, non-invasive ultrasound technique may be effectively used for diagnostics of some other anomalies, those are reported to be frequent in the sturgeon hatchery and farming practice, for example: cysts, tumors of different organs, notochord deformation, swimming bladder inflammation, liver and heart obesity, dropsy of the abdominal cavity, and foreign bodies (as well as stones) in the digestive system.

5.3.1 Inflammation of swimming bladder

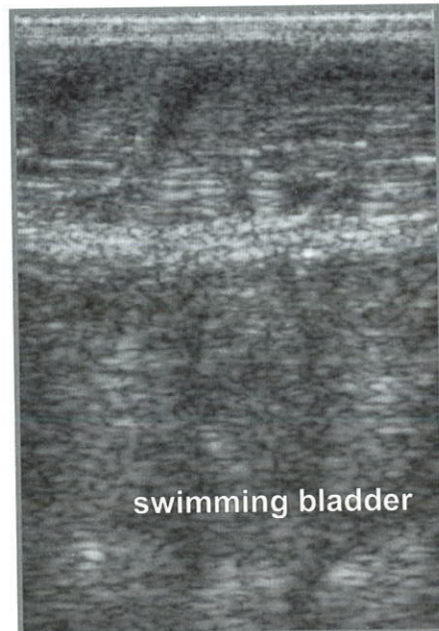


Fig. 5.10 Ultrasound image of inflammation swimming bladder of beluga.

Inflammation of swimming bladder encountered during some diseases, associated with its volume enlargement. On the ultrasound image (Fig. 5.10), the inflamed swimming bladder occupies entire area of scanning and appears as wide region of moderate echogenicity, that is shielded other inner organs.

At this, the diagnostics of gonad state in the location of scanning is difficult (gas does not transmit ultrasound), hence it is necessary to find optimal angle of scanning.

5.3.2 Notochord deformation

Notochord deformation (Fig. 5.11) can be caused by: traumas, unbalanced feed, violation of hydrochemical regime, cysts, tumors. Alterations in the area of cartilaginous notochord tunic, of inflammatory or tumor nature can appear as growing dilatational structures, those can be identified using ultrasound diagnostics.

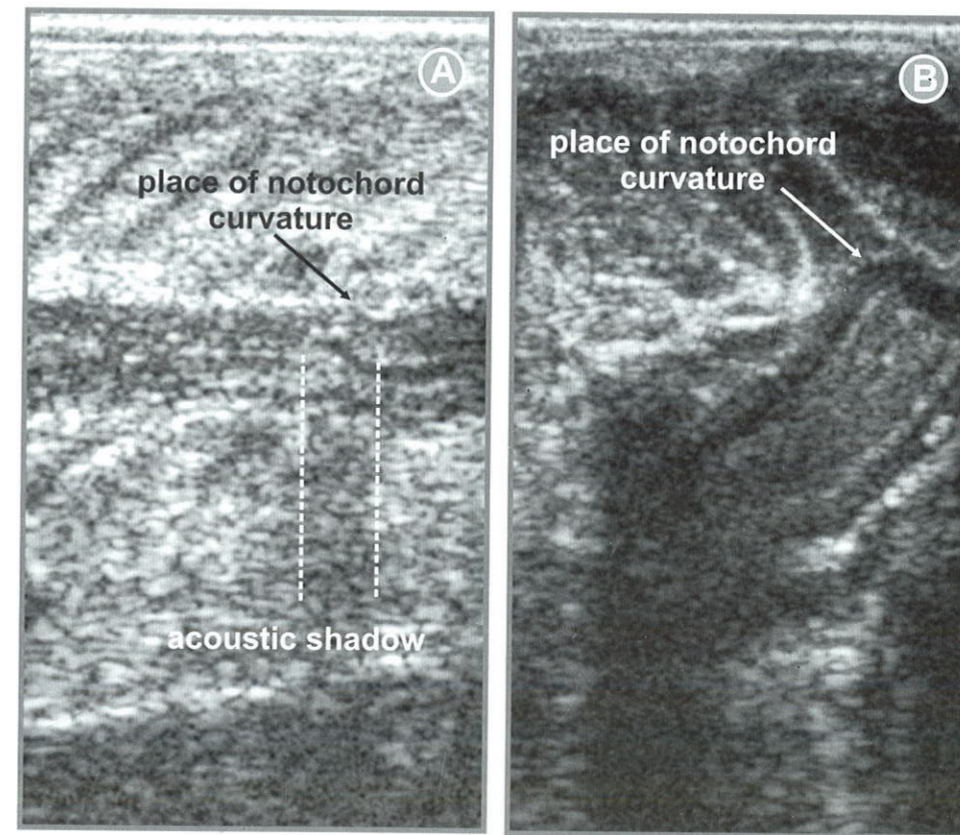


Fig. 5.11 Frontal (A) and transverse (B) ultrasound images of notochord deformation: A – Siberian sturgeon; B – beluga.

5.3.3 Foreign bodies in the digestive system

A stone in the intestine produces a bright echo from the front plane and dense acoustic shadow (Fig. 5.12). Similar cases are recorded for beluga at pond rearing, in relation with feeding behaviour – capture of feeds (prey).

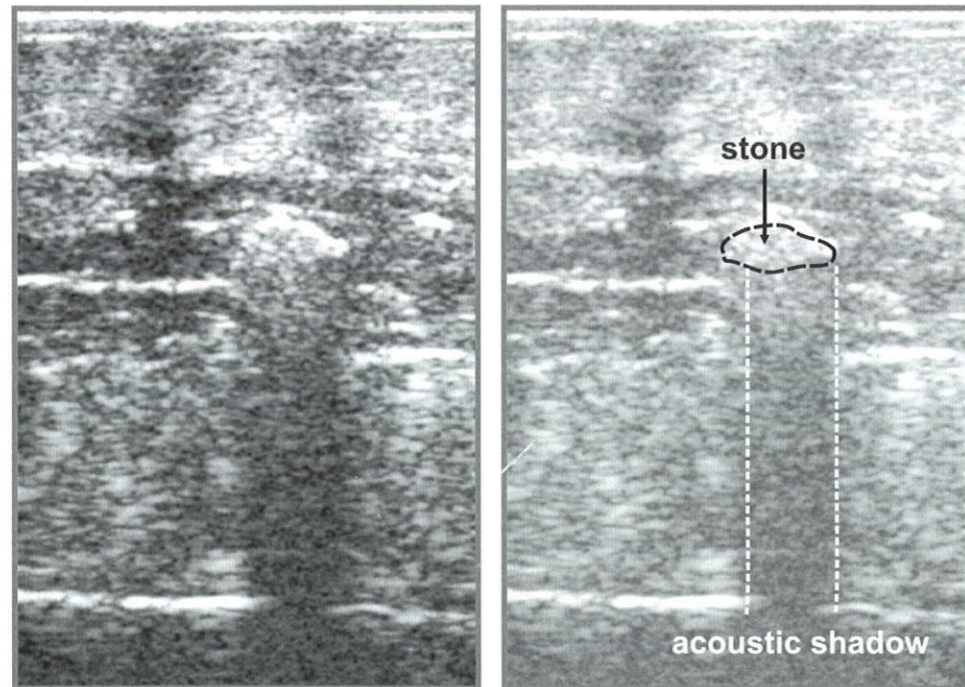


Fig. 5.12 Frontal ultrasound image of beluga intestine with a stone.

5.3.4 Optimal positioning of probes for biopsy

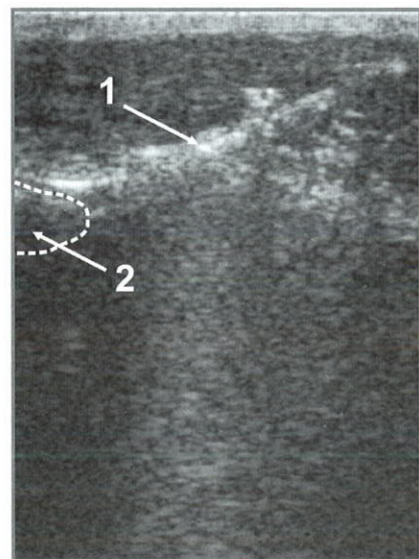


Fig. 5.13 Ultrasound image of gonad biopsy (1 – probe, 2 – gonad).

It is wise to use ultrasound technique for complicated cases of sampling, those require application of biopsy technique (bioplat) and optimal positioning of the probe, which allows accurate localization of gonads or other inner organs in sturgeons. This is especially urgent while conducting biopsy of small size sturgeons. In this case it would be helpful to use a special biopsy kit, including a biopsy guide adapter to transducer and needle guide, enabling the optimization of biopsy (Fig. 5.13).

In any case, the biopsy procedure can be performed in “Cine mode”.

5.4 Artefacts (false images)

Artefact in ultrasound is referred to signal information, that does not correspond to real anatomy of the experimental objects (distortion or vanished image).

To avoid false interpretation in the course of ultrasound diagnostics, it is very important to identify commonly occurred artefacts. Most typical of them are presented below.

5.4.1 Acoustic shadow

Acoustic shadow (Fig. 5.14) is an area behind the inner structures, those strongly reflected (scutes, intestine stones) or absorbing (gas) ultrasound, through which ultrasound waves fail to propagate. This area of attenuation appears on the ultrasound images as a black strip behind the scanning object.

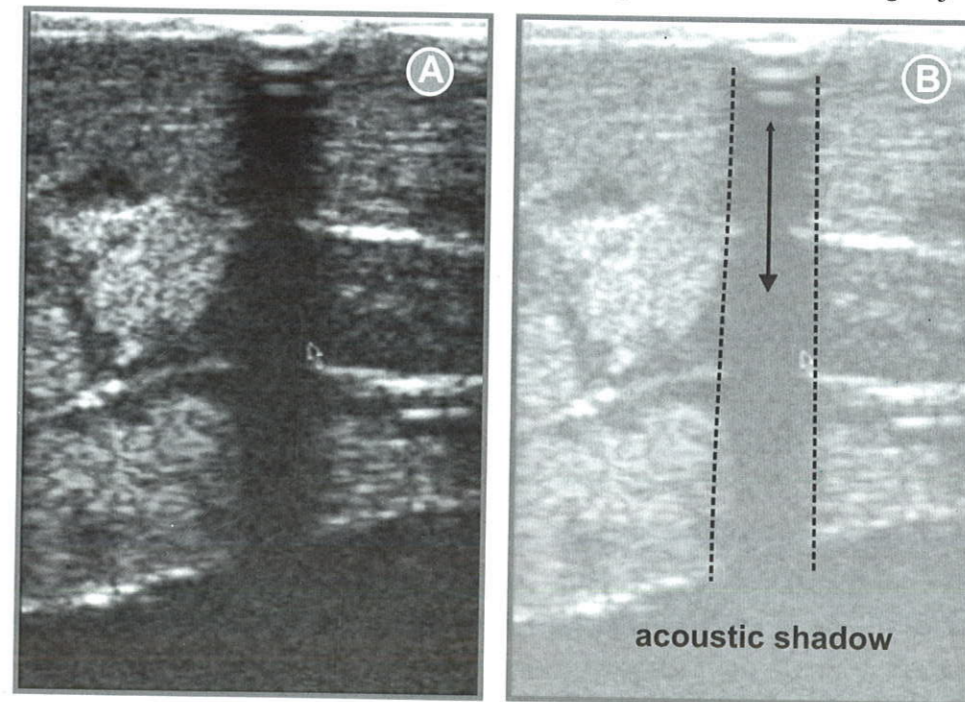


Fig. 5.14 Ultrasound image of acoustic shadow behind a lateral scute in stellate sturgeon.

Ability to identify this phenomenon is useful while defining the liquid nature of the scanning area on the image.

5.4.2 Distal acoustic pseudoenhancement

Distal acoustic pseudoenhancement of the signal (Fig. 5.15) at penetration of structures with low absorption ability (liquids, fluid formations) is characterized by decrease in signal damping and thus distal enhancement of acoustic energy behind this structure having a lower rate of signal damping.

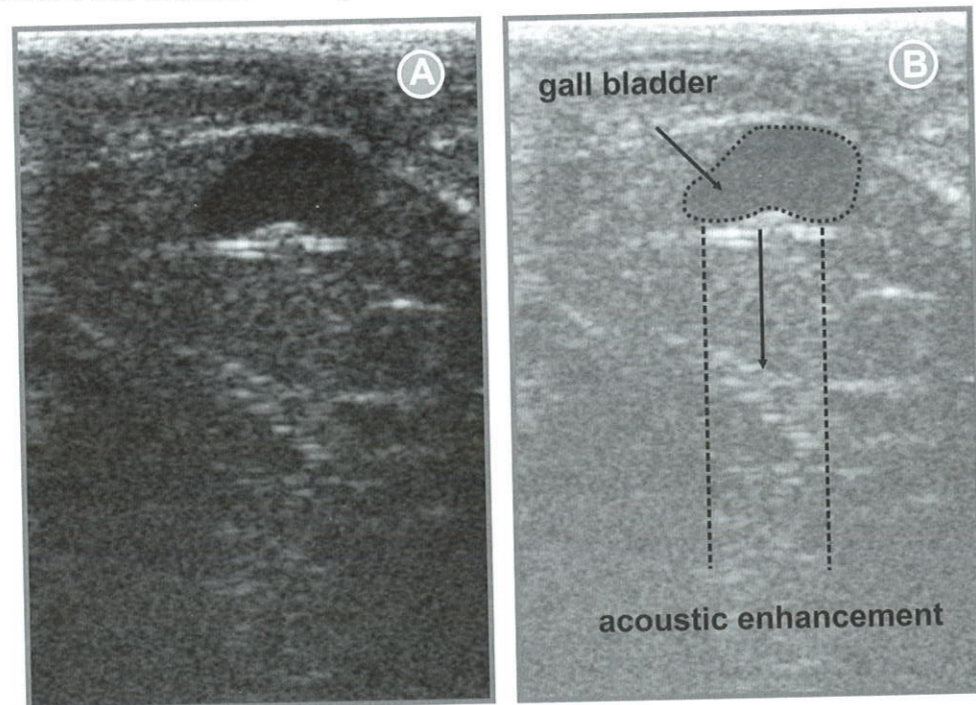


Fig. 5.15 Ultrasound image of distal acoustic enhancement behind gall bladder, characterized by echogenicity increase immediately behind anechoic area.

5.4.3 Reverberation

Reverberation (multiply reflection) is propagation of ultrasound beams between two (or more) closely spaced surfaces. Reverberation appears as periodical bright strips. Reverberation can occur in the course of ultrasound beam transmission between tissues of different acoustic resistance rates (Table 1.1). Reverberation can completely change images, creating linear structures or mirror reflections. One of the reverberation types called "comet tail" is occurred when ultrasound forces own oscillation of the object, which sends ultrasound impulses to the transducer, those can be defined on the ultrasound image as light strips behind the object.

5.4.4 Mirror reflection

Mirror reflection (Fig. 5.16) is a mirage of real structure, encountered behind the strongly reflecting border between media (tissues with different acoustic reflection). Sometimes this phenomenon is occurred at both sides of a strong reflector, of larger size then length of the ultrasound wave (for example, tissue membrane or vessel walls). Changing of the transducer position allows to reduce probability of the improper diagnostics, because partial or complete reflection depends on the incidence angle of ultrasound beam (Palmer et al., 1995).

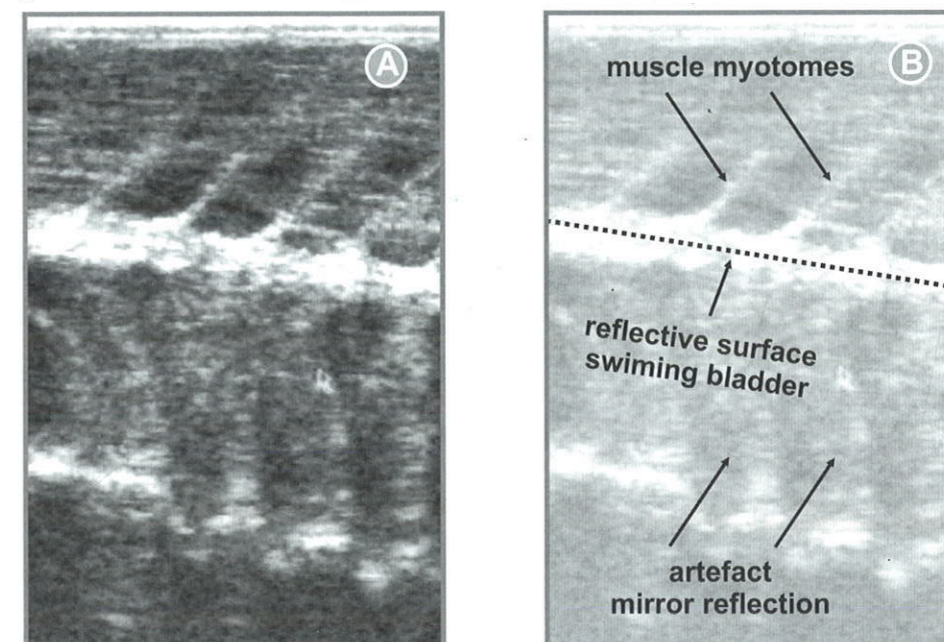


Fig. 5.16 Ultrasound image of mirror reflection artefact – duplication of muscle myotomes from swimming bladder.

5.4.5 Gas

Gas (Fig. 5.17) is referred to shielding of tissues and organs behind, as a result of the signal refraction and appearance of gas acoustic shadow.

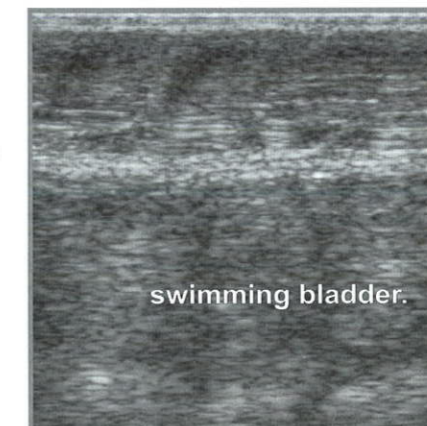


Fig. 5.17 Ultrasound image of shielding of scanning area, located behind swimming bladder.

5.5 Basic non-invasive measurements of linear and calculation of volumetric characteristics of inner organs using ultrasound express diagnostics

The problems (objectives) of inner organs measurements have been paid special attention in the practice of domestic broodstock management, as well as in the course of ichthyological studies. As a rule, similar measurements (typically weighting), not aimed at absolute values of weight of different organs (gonads, heart, liver, kidneys, spleen), but at relative (dimensionless) body weight associated indices (ratios).

Firstly, this is related to the gonadosomatic index (ratio gonad weight to fish weight), commonly used at studying of gonadogenesis dynamics both while studying sturgeons in natural water bodies (in the wild) (Trusov, 1964, Bruch et al., 2001) and, especially while analyzing sturgeon gonads status at different maturity stages in domestic broodstock (Doroshov et al., 1997, Chebanov et al., 2004, Williot et al., 2005).

Use of the so-called morphophysiological indices (indices of heart, spleen etc.) for comparative analysis of wild breeders of various terms of spawning run, age and sex have been also used rather frequently (Raspopov, Kobzeva, 2007). In addition, morphophysiological indices (cardiosomatic, hepatosomatic etc.) have been used in some investigations (Piskunova et al., 2001, Fedoseyeva et al., 2006) as indicators of holding conditions (grow-up, overwintering) of different age graded sturgeons at domestic broodstock establishment, estimation of peculiarities of developmental biology of some farmed sturgeons and hybrids.

At the same time, despite the effectiveness of gonadosomatic and morphophysiological indices application, necessity to sacrifice sturgeon in order to extract and weight inner organs is the prime disadvantage of these indices application. It is obvious, that such approach can not be used for development and implementation of Best Management Practice of sturgeon domestic broodstock, especially for rare and endangered species.

For this reason at formation and usage of living gene bank of 8 sturgeon species (Chebanov et al., 2002, 2004), it has been suggested to apply new characters – ratio of inner organs volume to the total fish body volume. The latter can be easily calculated by live fish immersion into graduated vessels. Volumes of some inner organs (gonads, heart etc.) can be calculated on the basis of linear characters measurements using non-invasive ultrasound express method.

Standard procedure of automatic measurements of segments, angles, perimeters and surface areas (Fig. 5.18), formed by closed circuits is typically presented in manuals of different digital ultrasound diagnostic systems.

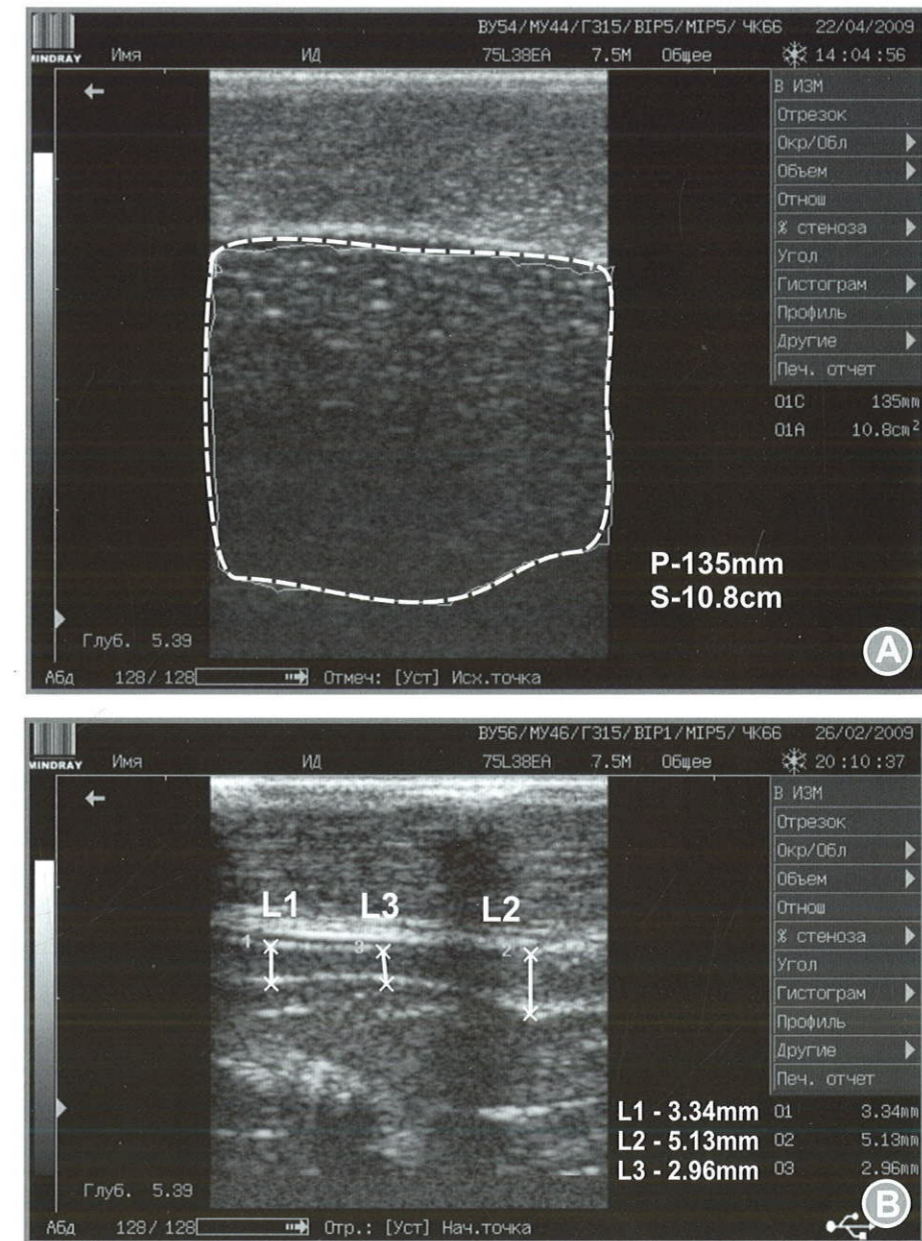


Fig. 5.18 Examples of automatic measurement of segments, perimeters (P) and surface areas (S) formed by closed circuit on the frontal ultrasound images of ovary (a) and testis (b).

Necessary measurements of linear sizes of inner organs (in the rectangular coordinate system) can be easily conducted using 'frame mode' of ultrasound scanning of inner organs (Chapter 4) taken at mode "B" of frontal and transverse scanning. Almost all ultrasound scanners have mode "Measure", thus enabling to perform and display automatic measurement (perimeters, square etc.) areas associated with moving of the cursor along the trajectories in question and fixation of initial and final points.

The segment division of an organ to lobes (Fig. 5.19) (dependent on shape changes) can be used to define volume of this organ. This enables to substitute the calculation of the total volume of an organ to mere calculation of single lobes (segments) using approximation by common geometric figures ellipsoid of revolution, cylinders, truncated cones etc).

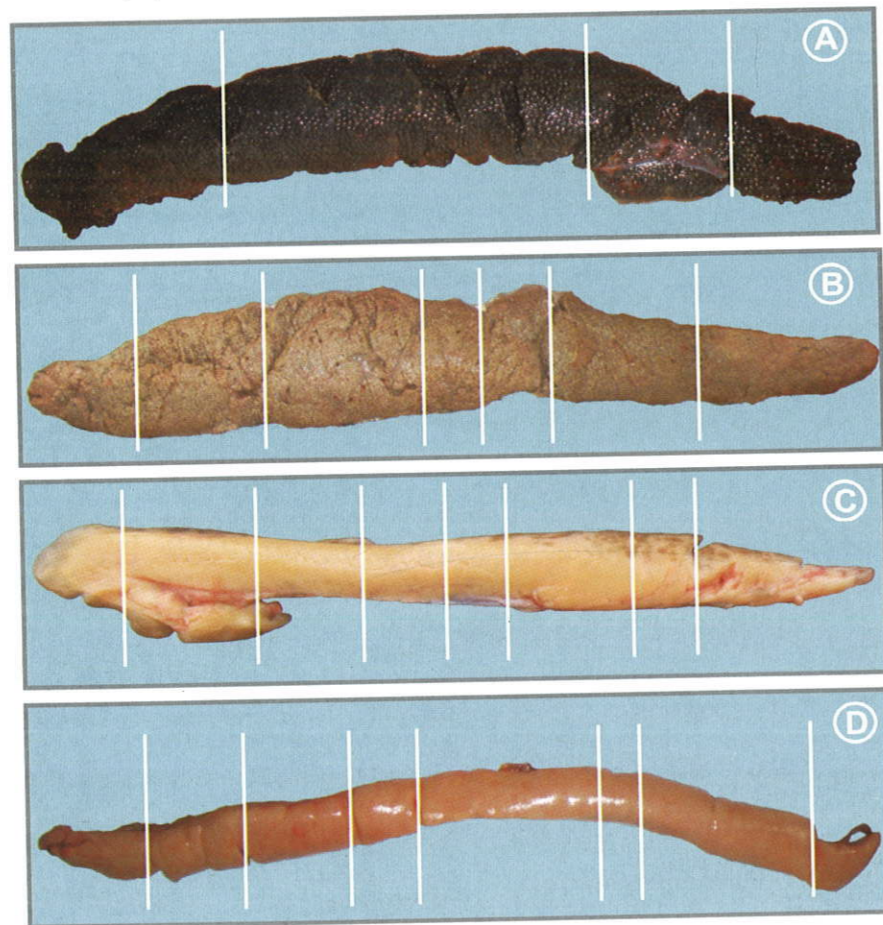


Fig. 5.19 Segment division of gonads at different maturity stages into lobes: a, b, c – female, d – male.

Automatic calculation of square areas of closed curves S_i , outlined on the ultrasound images by "control" transverse sections of single segments of inner organs (Fig. 5.20 & 5.21) and manual measurement of each segment length – l_i (between transverse sections) along the external fish surface (Fig. 5.22) allows to get source data for calculation of single segments volumes.

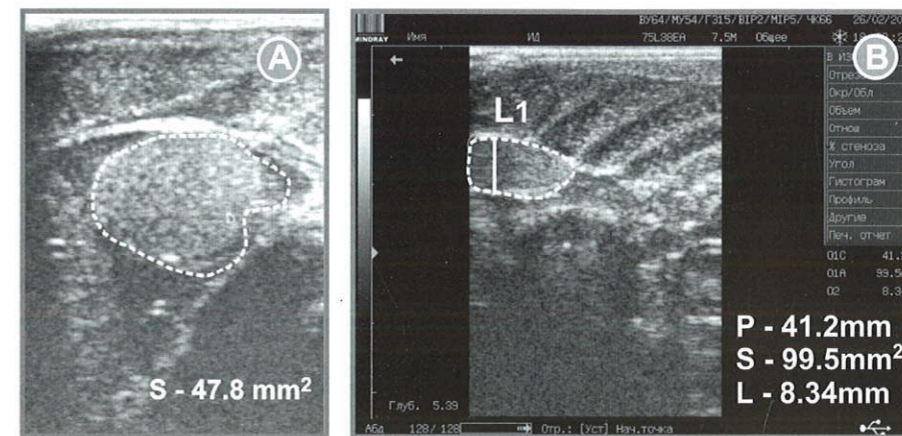


Fig. 5.20 Automatic measurement of surface areas (S_i) of transverse sections on separate testes segments on the ultrasound image.

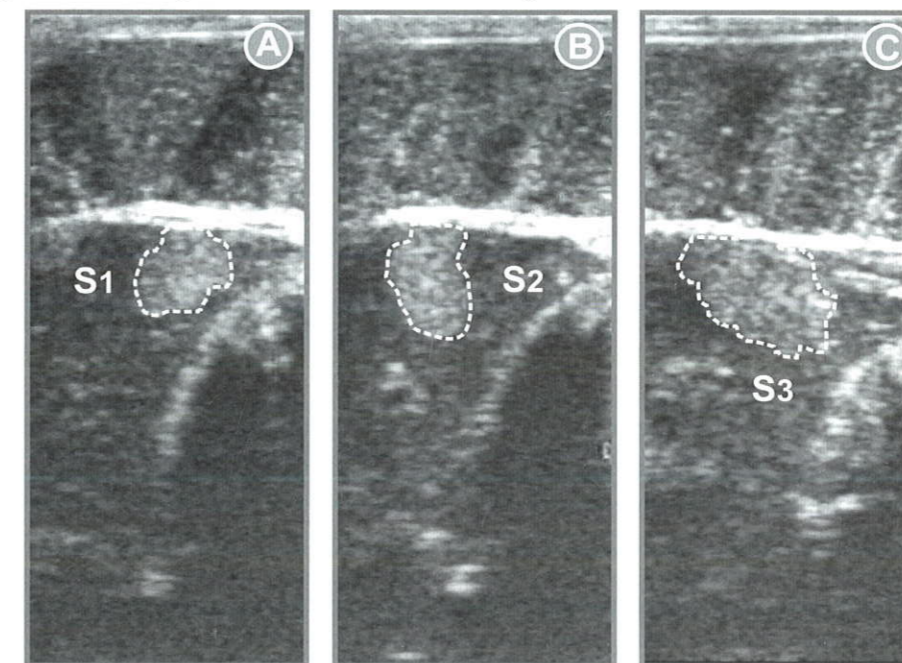


Fig. 5.21 Examples of transverse ultrasound images of separate segments of Russian sturgeon ovary for measurement of surface areas (S_1 - S_3).

In this case, for calculation of volumes of separate gonad segments (V_g) it is wise to use the following formulas:

1. For segment shape close to cylinder $V_{gi} = S_i \cdot l_i$

2. For segment shape close to truncated cone or pyramid:

$$V_{gi} = 1/3 l_i (S_i + S_{i+1} + \sqrt{S_i S_{i+1}}),$$

where:

S_i – surface area of transverse section number “i” of the gonad,

l_i – length of the gonad segment (lobe) number “i”,

S_{i+1} – surface area of transverse section number “i+1” of the gonad.

The accuracy of gonad volume calculation using these formulas will be defined by the number of segments (and vice versa) as well as by rate of longitudinal changes in gonad shape.

To reduce uncertainty of measurements, correcting coefficient may be used, those calculated using regression analysis of calculated and true volumes of inner organs in the course of control measurements for each sturgeon species.

Moreover, the volumes of ovaries at maturity stage IV, calculated with the help of ultrasound and volumes of mature (ripe) oocytes (on the basis of the diameters measured on the ultrasound images) (Fig. 5.23) or using selected eggs (using biopsy – Fig. 2.1) may allow the approximate forecast of absolute and relative fecundity of females before extraction eggs for sturgeon reproduction and for caviar production.

For instance, volume of oocytes (v), selected on the bases of biopsy, can be calculated, for example, using formula reported in Lenhardt et al. (2004), for Russian Danube sturgeon eggs:

$$V = 4/3 \times \pi \times D_1^2/2 \times D_2/2$$

Where D_1 and D_2 represent major and minor diameters of an egg respectively.

Errors of similar measurements and calculations of inner organs volumes in sturgeons would be decreased in the course of experience and adaptation of




Fig. 5.22 Measurement of each segment length (l_i) (between transverse sections) on the external surface of Russian sturgeon.

methods and standard calculation procedures used in medicine. But it should be noted that objective of the authors has been to find ways of effective and wide application of cheap ultrasound scanners in the sturgeon culture, especially systems used in veterinary, that is a bit complicated than use of more advanced and expensive medical ultrasound scanners, supplied with modern software for automatic calculation presented above.

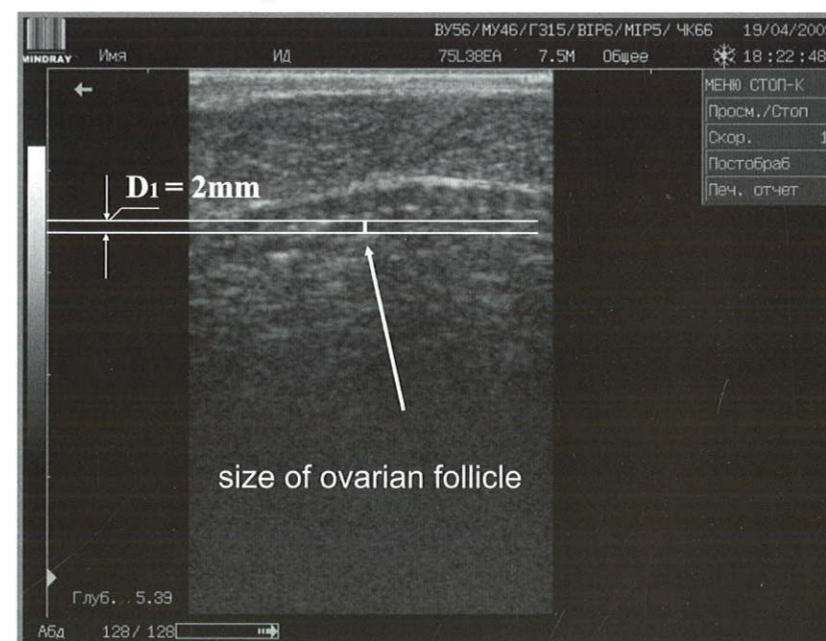


Fig. 5.23 Measurement of an oocyte diameter (D_1) on the frontal ultrasound image of sterlet ovary.

List species of the Acipenseriformes

<i>Species</i>	English name
<i>Acipenser baerii</i>	Siberian sturgeon
<i>Acipenser brevirostrum</i>	Shortnose sturgeon
<i>Acipenser dabryanus</i>	Yangtze (or Changjiang) sturgeon
<i>Acipenser fulvescens</i>	Lake sturgeon
<i>Acipenser gueldenstaedtii</i>	Russian sturgeon
<i>Acipenser medirostris</i>	Green sturgeon
<i>Acipenser mikadoi</i>	Sakhalin sturgeon
<i>Acipenser naccarii</i>	Adriatic sturgeon
<i>Acipenser nudiventris</i>	Ship sturgeon
<i>Acipenser oxyrinchus</i>	Atlantic sturgeon
<i>Acipenser persicus</i>	Persian sturgeon
<i>Acipenser ruthenus</i>	Sterlet
<i>Acipenser schrenckii</i>	Amur sturgeon
<i>Acipenser sinensis</i>	Chinese sturgeon
<i>Acipenser stellatus</i>	Stellate sturgeon
<i>Acipenser sturio</i>	Atlantic (Common sturgeon)
<i>Acipenser transmontanus</i>	White sturgeon
<i>Huso dauricus</i>	Kaluga
<i>Huso huso</i>	Beluga
<i>Pseudoscaphirhynchus fedtschenkoi</i>	Syr-Dar shovelnose sturgeon
<i>Pseudoscaphirhynchus hermanni</i>	Small Amu-Dar shovelnose sturgeon
<i>Pseudoscaphirhynchus kaufmanni</i>	Large Amu-Dar shovelnose sturgeon
<i>Scaphirhynchus albus</i>	Pallid sturgeon
<i>Scaphirhynchus platorynchus</i>	Shovelnose sturgeon
<i>Scaphirhynchus suttkusi</i>	Alabama sturgeon
<i>Polyodon spathula</i>	Paddlefish
<i>Psephurus gladius</i>	Chinese paddlefish

Conclusion

All mentioned above has proved the fact that ultrasound diagnostic is a highly informative and available non-invasive express technique for sexing and maturity staging, that can strongly assist in optimization of management control of farmed broodstock.

It is important to note that even nowadays, this method may enable early, 3-6 years prior to maturity (depending on the species) selection of not only males intended for selling, but also early mature females (from each generation) for broodstock and caviar production.

We should also note, that, owing to the implementation of described in this book diagnostic methods one of the largest genetic heterogenous broodstocks of 8 sturgeon species has been established (Chebanov, Billard, 2001). The mass maturation of farmed females of some sturgeon species (Azov beluga, stellate, ship, Russian and Persian sturgeons) reared only on the artificial feeds and obtaining of viable progeny from them, firstly in sturgeon culture, has been conducted annually starting from the year 2000.

In nearest future this method allows to perform non-invasive monitoring of sex structure and dynamics of gametogenesis in the course of fundamental studies aimed at evaluation of gynogenetic offspring of different sturgeon species (Batrdinov et al., 2008), dispermic androgenesis of endangered sturgeon species (Grunina et al., 2009), evaluation of different factors impact on the development of gonad regulation (Wurtz et al., 2005) and assist in other direction of activity conducted with different sturgeon species from living gene bank of South Branch Federal Centre of Selection and Genetics for Aquaculture.

References

- Akhundov M.M. 1997. The plasticity of gonadal sex differentiation of sturgeon. Baku. Elm. 200 pp. (in Russian).
- Amiri B.M., Maebayashi M., Adachi S., Yamauchi K. 1996. Testicular development and serum sex steroid profiles during the annual sexual cycle of the male sturgeon hybrid, the bester // *J. Fish Biol.* 48: 1039-1050.
- Artyukhin E.N. 2008. Sturgeons (ecology, geographic distribution and phylogeny). St. Petersburg: Publ. house of St. Petersburg University. 137 pp. (in Russian).
- Atlas of Abnormalities in Gametogenesis and Postembryonal Morphology of Sturgeons / Akimova N.V., Goryunova V.B., Mikodina E.V., Nikolskaya M.P., Ruban G.I., Sokolova S.A., Shagayeva V.G., Shatunovskiy M.I. 2004. Moscow: VNIRO Publishing. 120 pp.
- Badrtidinov O.A., Kovalev K.V., Lebedeva E.B., Vasil'eva E.D., Recoubratsky A.V., Grunina A.S., Chebanov M.S., Vasil'ev V.P. 2008. Entirely male Gynogenetic Offspring of *Acipenser stellatus* // *Reports of Russian Academy of Science*, 423. Nos. 1-6: 392.
- Bahmani M., Kazemi R., Hallajian A. 2005. Workshop on Sturgeon Sexing and Gonad Staging // 5th Intern. Symp. on Sturg., May 9-13, Ramsar, Iran. 20 pp.
- Barannikova I.A., Bayunova L.V., Semenkova T.B. 2005. Serum sex steroids and their specific cytosol binding in the pituitary and gonads of Russian sturgeon (*Acipenser gueldenstaedtii* Brandt) during final maturation // *J. Appl. Ichthyol.* 22: 331-333.
- Barannikova I.A., Burtsev I.A., Vlasenko A.D., Gershanovich A.D., Makarov E.V., Chebanov M.S. 1995. Sturgeon fisheries in Russia // *Proc. 2th Intern. Sturg. Symp.*, Moscow. VNIRO. 124-130.
- Billard R., Lecointre G. 2001. Biology and conservation of sturgeon and paddlefish. *Reviews in Fish Biology and Fisheries.* 10: 355-392.
- Bilio M. 2007. Controlled reproduction and domestication in aquaculture // *Aquaculture Europe.* 32 (1): 5-14.
- Bonput E. 2006. Sexage des sturgeons par echographie. *AquaFilia.* 12: 5-8.
- Bruch R. M., Dick T.A., Choudhury A. 2001. A practical field guide for the identification of stages of lake sturgeon gonad development with notes on lake sturgeon reproductive biology and management implications. *Publ. Sturgeon for Tomorrow*, Malone, WI. USA. 38 pp.
- Bruch R. P. (ed.) 2002. *Esturgeons et caviar*. Laurent Sabeau, Paris: Tec et Doc. 298 pp. (in French).
- Chang J., 1999. Studies on the structure character and trend of Chinese sturgeon in the Yangtze River. Institute of Hydrobiology, Chinese Academy of Sciences. Wuhan. Hubei. PhD-Thesis. 150 pp. (in Chinese with English summary).
- Chebanov M.S. 2005. Conservation culture of sturgeons in the Azov Sea Basin // 1st Intern. Workshop on the Biology. Conservation and Sustainable Development of Sturgeons in Southern Europe. Granada. Spain. 69-73.
- Chebanov M.S., Billard, R. 2001. The culture of sturgeons in Russia: production of juveniles for stocking and meat for human consumption // *Aquat. Living Resour.* 14: 375-381.
- Chebanov M.S., Chmyr Yu.N., 2002. New method of sturgeon culture optimization // *Moscow, Rybovodstvo I Rybolovstvo (Fish Farming and Fishing).* 1: 20-21 (in Russian).
- Chebanov M.S., Chmyr Yu.N. 2005. Early sexing and staging of farmed and wild sturgeon juveniles by using ultrasound technique // 5th International Symposium on Sturgeon. Ramsar. Iran. Extended Abstracts Aquaculture. 33-35.
- Chebanov M.S., Galich E.V. 2008. Chinese sturgeon (*Acipenser sinensis* Gray): artificial reproduction and brood stock optimization by using ultrasound technique of sexing and gonad maturity staging // *Sturgeon culture.* 2: 43-58 (in Russian).
- Chebanov M.S., Galich E.V., Ananyev D.V. 2008. Strategy for conservation of sturgeon under the conditions of the Kuban River flow regulation // *Special Publication of the World Sturgeon Conservation Society.* 2: 70-82.
- Chebanov M.S., Galich E.V., Chmyr Yu.N. 2004. Sturgeon breeding and rearing handbook. Moscow, «Rosinformagrotech». 136 pp. (in Russian).
- Chebanov M.S., Galich E.V., Ostapenko V.A., Chmyr Yu.N. 2006. Production of Farmed Sturgeon Caviar: from experiments to acceleration of commercial production // *Moscow, J. Fish Farming.* 3-4: 20-23. (in Russian).
- Chebanov M.S., Karnaukhov G.I., Galich E.V., Chmyr Yu.N. 2002. Hatchery stock enhancement and conservation of sturgeon, with an emphasis on the Azov Sea populations // *J. Appl. Ichthyol.* 18: 463-469.
- Chebanov M.S., Savelyeva E.A. 1999. New strategies for brood stock management of sturgeon in the Sea of Azov basin in response to changes in patterns of spawning migration // *J. Appl. Ichthyol.* 15: 183-190.
- Conte F.S., Doroshov S.I., Lutes P.B., Strange E.M. 1988. Hatchery manual for the white sturgeon *Acipenser transmontanus* Richardson with application to other north American *Acipenseridae*. University of California, Division of Agriculture and Natural Resources, Oakland, California. 104 pp.
- Dettlaff T.A., Ginsburg A.S., Schmalhausen O.I. 1993. *Sturgeon Fishes. Developmental Biology and Aquaculture.* Springer Verlag, Berlin. 300 pp.
- Doroshov S.I., Moberg G.P., Van Eenennaam J.P. 1997. Observation on the reproductive cycle of cultured white sturgeon, *Acipenser transmontanus* // *Environmental Biology of Fishes.* 48: 265-278.
- Fan X., Wei Q., Chang J., Rosenthal H., He J., Chen D., Shen L., Du H., Yang De-Guo. 2006. Observations on the formation and development of the primary germinal tissue of cultured Chinese sturgeon, *Acipenser sinensis* // 5th Intern.

- Symp. on Sturg., Ramsar, Iran, May 9 to 13, 2005. *J. Appl. Ichthyol.* 22 (Suppl.1): 358-360.
- Fedoseeva E.A., Raspopov V.M., Astafyeva S.S. 2006. Comparative analysis of organic-somatic indices of sturgeon hybrids of natural generation and those produced artificially // 4th Intern. Scientific-and-practical conference. Sturgeon Aquaculture: achievements and prospects for development. Reports, March 13-15, 2006. Astrakhan, Russia. 60-62 (in Russian).
- Gershanovich A.D., Smith T.I.J. 1995 (ed.). Intern. Symp. on Sturg., Sept. 1993, Moscow, VNIRO. 350 pp.
- Goddard P.G. 1995. Veterinary Ultrasonography, CABI, Pub. 293-297.
- Goncharov B.F., Skoblina M.N., Trubnikova O.B., Chebanov M.S. 2009. Influence of Temperature on the Sterlet (*Acipenser ruthenus* L.) Ovarian Follicles State in Biology, Conservation and Sustainable Development of Sturgeons // *Fish & Fisheries Series.* 29: 205-214.
- Gurtovoy N.N., Matveev B.S., Dzerjinskiy F.Y. 1976. Practical zootomy of vertebrates. Moscow. 351 pp. (in Russian).
- Grunina A.S., Recoubratsky A.V., Barmintsev V.A., Tsvetkova L.I., Chebanov M.S. 2009. Dispemic androgenesis as a method of recovering endangered sturgeon species in Biology, Conservation and Sustainable Development of Sturgeons // *Fish & Fisheries Series.* 29: 187-204.
- Hochleithner M., Gessner I. 1999. Sturgeons and Paddlefishes (*Acipenseriformes*) of the world Biology and Aquaculture. AquaTech. Public. Austria. 165 pp.
- Karlsen O., Holm J.C. 1994. Ultrasonography, a noninvasive method for sex determination in cod (*Gadus morhua*) // *J. Fish Biol.* 44: 965-971.
- Lenhardt M., Finn R.N., Cakic P., Kolarevic J., Krpo-Cetkovic J., Radovic I., Fyhn H.J. 2004. Analysis of the post-vitellogenic oocytes of the three species of Danubian *Acipenseridae* // *Belg. J. Zool.* 134 (Suppl. 1): 77-79.
- Maltsev A.V., Merkulov Y.G. 2006. Biometric method for sex identification in sturgeons, in particular the Russian sturgeon *Acipenser gueldenstaedtii* (*Acipenseridae*) of the Azov population // *Ichthyol.* 46. Issue 4: 536-540 (in Russian).
- Mattson N.S. 1991. A new method to determination sex and gonad size in live fishes by using ultrasonography // *J. Fish Biol.* 39: 673-677.
- Moghim M., Vajhi A.R., Veshkini A., Masoudifard M. 2002. Determination of sex and maturity in *Acipenser stellatus* by using ultrasonography // *J. Appl. Ichthyol.* 18: 325-328.
- Mohler J.W. 2003. Culture manual for the Atlantic sturgeon (*Acipenser oxyrinchus desotoi*) // US Fish & Wildlife Service. Hadly. 68 pp.
- Moiseeva E.B., Fedorov S.I., Parfenova N.A. 1997. Abnormalities of Azov Sea sturgeon (*Acipenseridae*) females gonad formation // *Ichthyol.* 37: 660-666.

- Palmer P.E.S., Breyer B., Bruguera C.A., Gharbi H.A., Goldberg B.B., Tan F.E.H., Wachira M.W., Weill F.S. 1995. Manual on diagnostic ultrasound. World Health Organization. Geneva. 334 pp.
- Parauka F.M. 1993. Guidelines for artificially spawning gulf sturgeon (*Acipenser oxyrinchus desotoi*) // US Fish & Wildlife Service. Panama City. 1993. 33 pp.
- Persov G.M. 1975. Sex differentiation of fish. Leningrad: Publishing house of Leningrad State University. 148 pp. (in Russian).
- Piskunova L.V., Chernova P.V., Marinova G.P., Magzanova D.K. 2001. Physiological and biochemical and histological evaluation of sturgeon broodstock in the Astrakhan region. Fish farm researches in the Caspian Sea // Results of NIR research in 2000. Astrakhan: KaspNIRKh. 310-320 (in Russian).
- Podushka S.B. 2008. Sex dimorphism in the pectoral fins form in the Amur sturgeon // *Sturgeon culture.* 2: 69-71 (in Russian).
- Podushka, S.B. 1986. Methods of egg obtaining in sturgeon with life preservation. Author's license 141035. Methods for obtaining eggs from fish females. Committee on Inventions and Discoveries, Council of Ministers of the USSR (in Russian).
- Podushka S.B., Chebanov M.S. 2007. Caviar oriented sturgeon culture in China // Scientific and Technical Bulletin of INENKO Ichthyology laboratory. 13: 5-15 (in Russian).
- Ramsar Declaration on Global Sturgeon Conservation. 2006 // *J. Appl. Ichthyol.* 22 (Suppl. 1): 5-11.
- Raspopov V.M., Kobzeva T.N. 2007. Ecological bases of sturgeons reproduction in present runoff of Volga River. Astrakhan: ASTU. 156 pp. (in Russian).
- Rosenthal H., Bronzi P., Mc Kenzie D. 1999. Highlights of the 3th Intern. Sturg. Symp.: Session Summaries, Conclusions and Recommendations // *J. Appl. Ichthyol.* 15: 1-6.
- Rosenthal H., Bruch R. M., Binkovski F. P., Doroshov S.P. 2002. Highlights of the 4th Intern. Sturg. Symp.: Session Summaries, Conclusions and Recommendations // *J. Appl. Ichthyol.* 18: 221-225.
- Rosenthal H., Pourkazemi M., Bruch R.M. 2006. The 5th Intern. Symp. on Sturg.: A conference with major emphasis on conservation, environmental mitigation and sustainable use of the sturgeon resources // *J. Appl. Ichthyol.* 22 (Suppl. 1): 1-11.
- Safronov A.S., Solokhin I.V., Nikolaev A.I., Burlatchenko I.V., Filippova O.P., Dudin K.V. 2006. Use of a borescope for early intravital identification in sturgeons // *Sturgeon Aquaculture: Achievements and Prospects for Development.* Astrakhan. 121-124.
- Semenkova T.B., Bayunova L.V., Kolmakov N.N., Barannikova I.A. 2006. Using of sex steroids levels assay in early sex identification in sturgeon // *Sturgeon Aquaculture: Achievements and Prospects for Development.* Astrakhan. 124-126.

- Semenkova T.B., Canario A.V., Bayunova L.V., Couto E., Kolmakov N.N., Barannikova I.A. 2005. Sex steroids and oocyte maturation in the sterlet (*Acipenser ruthenus* L.) // *J. Appl. Ichthyol.* 22: 340-345.
- Trusov V.Z. 1972. Maturation of Volga-Caspian sturgeon (*Acipenser gueldenstaedtii*) gonads in maritime period of life // *Trudy TsNIORKh* 4: 95-122 (in Russian).
- Vaini F., Pazzaglia M., Ruzza C. 2001. Female identification and checking of ovary development in caviar producing white sturgeon (*Acipenser transmontanus*) – Preliminary results // *Extended Abstracts of 4th Intern. Symp. on Sturg., Oshkosh, WI, USA.* PP96.
- Vajhi A.R., Masoudifard M., Veshkini A., Akhtarzadeh M., Moghim M. 2001. Normal ultrasonographic findings of the digestive system of Persian Sturgeon (*Acipenser gueldenstaedtii persicus*) // *Extended Abstracts of 4th Intern. Symp. on Sturg., Oshkosh, WI, USA.* PP97.
- Van Eenennaam J.P., Bruch R., Kroll K. 2001. Sturgeon sexing, staging maturity and spawning induction workshop // *Extended Abstracts of 4th Intern. Symp. on Sturg., Oshkosh, WI, USA.* 50 pp.
- Van Eenennaam J.P., Doroshov S. I. 1998. Effects of age and body size on gonadal development of Atlantic sturgeon // *J. Fish Biol.* 53: 624-637.
- Vecsei P., Litvak M.K., Noakes D.L.G., Rien T., Hochleithner M. 2003. A noninvasive technique for determining sex of live adult North American sturgeons // *Env. Biol. Fish.* 68: 333-338.
- Vladikov V.D. 1931. Poissons de la Russie Sous-Carpathique (Tchecoslovaquie). *Mem. Soc. Zool. France* 29: 217-374. Cited in: Hoicik J. (ed.) 1989. *The Freshwater Fishes of Europe. I part II. General Introduction to Fishes Acipenseriformes.* AULA-Verlag, Wiesbaden.
- Webb M.A.H., Feist G.W., Foster Eu.P., Schreck C.B., Fitzpatrick M.S. 2001. Classification of sex and stage of maturity of white sturgeon (*Acipenser transmontanus*) using blood plasma and mucus indicators // *Extended Abstracts of 4th Intern. Symp. on Sturg., Oshkosh, WI, USA.* LH73.
- Wei Q., Ke Fuen, Zhang J., Zhuang P., Luo J., Zhou R., Yang W. 1997. Biology, fisheries and conservation of sturgeons and paddlefish in China // *Env. Biol. Fish.* 48: 241-255.
- Williot P., (ed.) 1989. *Acipenser. Cemagref Antoni.* 519 pp.
- Williot P. 2002. Reproduction // *Esturgeons et caviar* (dir R. Billard), pref. Laurent Sabeau. Paris: Tec et Doc. 63-90 (in French).
- Williot P., Arlati G., Chebanov M.S., Gulyas T., Kasimov R., Kirschbaum F., Patriche N., Pavlovskaya L.P., Poliakova L., Pourkazemi M., Kim Yu., Zhuang P., Zholdasova I.M. 2002. Status and management of Eurasian sturgeon: an overview // *Intern. Review of Hydrobiology.* 87. Issue 5-6: 483-506.
- Williot P., Brun R. 1998. Ovarian development and cycles in cultured Siberian sturgeon, *Acipenser baerii* // *Aquatic Living Resources.* 11: 111-118.

- Williot P., Brun R., Rouault T., Pelard M., Mercier D., Ludwig A. 2005. Artificial spawning in cultured sterlet sturgeon, *Acipenser ruthenus* L., with special emphasis on hermaphrodites // *Aquaculture.* 246: 263-273.
- Wuertz S., Nitsche A., Gessner J., Kirschbaum F., Kloas W. 2005. IGF-I and its role in maturing gonads of female sterlet, *Acipenser ruthenus* Linnaeus, 1758 // *J. Appl. Ichthyol.* 22: 346-352.
- Xiao H., Liu D., Tang D., Guo B. 2005. Structural and quality changes in the spawning stock of the Chinese sturgeon *Acipenser sinensis* below the Gezhouba Dam (Yangtze River). 5th Intern. Symp. on Sturg., Ramsar, Iran, May 9 to 13, 2005 // *J. Appl. Ichthyol.* 22: 111-115.
- Zubova S.E. 1971. Time of gonads differentiation and correlation of males and females of Volga sterlet sturgeon juveniles // *Ichthyol.* 11. Issue 3: 524-526.

Contents

	Introduction	3
1	Basis of Ultrasound Diagnostics in Sturgeon Broodstock Management	5
1.1	Equipment for sexing in sturgeons using ultrasound	5
1.1.1	Characteristics of ultrasound waves	7
1.1.2	Transducers	8
1.1.3	Some field ultrasound scanning systems used in aquaculture	10
1.1.4	Mobile data and analytical system on the basis of the ultrasound scanner Mindray DP-6600	13
1.2	Work Place Organization	15
1.3	The resolving capacity of sonography method for the sex Early life-time diagnostics and gonads maturity stages determination for sturgeons	17
	Glossary of special terms on ultrasound investigations	19
2	Sexing and Staging in Live Sturgeons Techniques Overview	21
2.1	Biopsy	21
2.2	Laparoscopy and direct palpation	22
2.3	Endoscopy	23
2.4	Sex steroid profiles analysis	25
2.5	Morphometry	27
2.6	Revealing of some external sex traits in adult sturgeons	28

3	Anatomic Structure and Non-invasive Detecting of Inner Organs and Tissues in Sturgeons by Ultrasound Technique	31
3.1	Anatomic structure of inner organs	31
3.1.1	Reproductive system	
3.1.2	Excretory system	
3.1.3	Digestive system	
3.1.4	Other inner organs	
3.2	Non-invasive detection of organs and tissues by ultrasound technique	
3.2.1	Scanning procedure schedule	36
3.2.2	Peculiarities of organs visualization at frontal ultrasound scanning	37
3.2.3	Peculiarities of organs visualization at transverse ultrasound scanning	39
4	Early Sexing and Staging Maturity of Sturgeons by Using Non-invasive Express Ultrasound Technique	41
4.1	Onset of anatomical differentiation of gonads	41
4.2	Analysis of ultrasound images of different stage of testes development	42
4.2.1	Male maturity stage I (M1)	42
4.2.2	Male maturity stage II (M2)	44
4.2.3	Male maturity stage II semi-fatty (M2sf)	46
4.2.4	Male maturity stage II fatty (M2f)	48
4.2.5	Male maturity stage III (M3)	50
4.2.6	Male maturity stage IV (M4)	53

4.2.7	Male maturity stage V (M5)	55
4.3	Analysis of ultrasound images of ovaries at different maturity stages	56
4.3.1	Female maturity stage I (F1)	56
4.3.2	Female maturity stage II (F2)	59
4.3.3	Female maturity stage II semi-fatty (F2sf)	62
4.3.4	Female maturity stage II fatty (F2f)	64
4.3.5	Female maturity stage II-III (F2-3)	67
4.3.6	Female maturity stage III (F3)	68
4.3.7	Female maturity stage IV incomplete (F4i)	70
4.3.8	Female maturity stage IV incomplete (F4i)	72
4.3.9	Female maturity stage V (F5)	73
4.3.10	Female maturity stage VI (F6)	74
4.4	Ultrasound images of mature testes and eggs resorption	
4.4.1	Males	76
4.4.2	Females	76
4.5	Non-invasive ultrasound monitoring of gonadogenesis of large sturgeon specimens	78
5	Functional Ultrasound Non-invasive Diagnostics of Inner Organs in Sturgeons	83
5.1	Ultrasound images of internal organs in sturgeons	83
5.1.1	Cartilaginous tunic of notochord	84
5.1.2	Kidneys	84
5.1.3	Liver	85
5.1.4	Gall bladder	86
5.1.5	Heart	86
5.1.6	Blood vessels	87
5.1.7	Pyloric gland	88

5.2	Ultrasound non-invasive diagnostics of developmental anomalies in the reproductive system of sturgeon (pathologic echoanatomy)	88
5.2.1	Lobularity of testes	89
5.2.2	Cyst	90
5.2.3	Sklerotization	91
5.2.4	Fatty degeneration of ovaries	
5.2.5	Hermaphroditism	91
5.3	Inflammation of swimming bladder	92
5.3.1	Express diagnostics of diseases and traumas of sturgeons internal organs	92
5.3.2	Notochord deformation	93
5.3.3	Foreign bodies in the digestive system	93
5.3.4	Optimal positioning of probes for biopsy	94
5.4	Artefacts (false images)	95
5.4.1	Acoustic shadow	95
5.4.2	Distal acoustic pseudoenhancement	96
5.4.3	Reverberation	96
5.4.4	Mirror reflection	97
5.4.5	Gas	97
5.5	Basic non-invasive measurements of linear and calculation of volumetric characteristics of inner organs using ultrasound express diagnostics	98
	List species of the Acipenseriformes	104
	Conclusion	105
	References	106

Mikhail S. Chebanov

Elena V. Galich

Ultrasound Diagnostics for Sturgeon Broodstock Management

Книга печатается в авторской редакции

Подписано в печать 30.09.09. Формат 70×100_{1/16}.
Печать офсетная. Уч.-изд.л. 9,35.
Тираж 500 экз. Заказ № 9328.

Тираж отпечатан с оригинал-макета заказчика
в типографии ООО «Просвещение-Юг»
350059 г. Краснодар, ул. Селезнева, 2. Тел./факс: 239-68-31.

Mikhail CHEBANOV and Elena GALICH

**ULTRASOUND DIAGNOSTICS
FOR SURGEON BROODSTOCK
MANAGEMENT**

Early sexing and staging
maturity of sturgeons
using non-invasive express
ultrasound technique

Ultrasound non-invasive
diagnostics of developmental
anomalies in the reproductive
system and internal organs of
sturgeons

Basic express measurements
of linear and calculation of
volumetric characteristics of
inner organs (gonadosomatic
and other indices, fecundity
etc.) using ultrasound
diagnostics

ISBN 978-5-93491-259-9